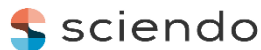

ORIGINAL RESEARCH



DOI: 10.2478/asmj-2022-0010

Cephalometric evaluation of adenoids and upper airway.

Réka Soós¹, Henrietta Hilda Kallós², Aurița Albu¹, Júlia Szabó¹, Krisztina Mártha¹¹ George Emil Palade University of Medicine, Pharmacy, Science, and Technology of Târgu-Mureș, Romania² PhD candidate, Doctoral School of Medicine and Pharmacy, George Emil Palade University of Medicine, Pharmacy, Science, and Technology of Târgu Mureș, Romania

Abstract

Cephalometric analysis performed on lateral X-ray allow orthodontists to evaluate soft tissues as well. Enlargement of adenoids, changes of the position of the tongue can be diagnosed parallel with skeletal assessment.

Our purpose was to investigate the skeletal growth direction and the posterior airway depth in mouth breather patients and to underline the importance of a complex cephalometric analysis prior orthodontic treatment.

30 mouth breather patients were selected from our database (17 boys and 13 girls, age 10.8 ± 1.2), in every case ENT examination confirmed the hypertrophy of adenoids. From the same database 30 patients with normal breathing pattern (17 boys and 13 girls, age 11.1 ± 0.9) for the control group. For every patient, the size of the adenoids, the depth of the palate and the position of the tongue. After filtering out the outliers in GraphPad-InStat system, standard deviation (\pm SD) was calculated, descriptive analytical statistics were performed.

Statistically significant differences were recorded regarding: 1.) the distance between adenoid vegetation and the palate ($p=0.014$, mouth breathers mean $9.76 \pm$ SD 3.04; control group mean $14.38 \pm$ SD 4.41), 2.) the distance between Sella and the adenoids ($p=0.186$, study group mean $33.39 \pm$ SD 4.39; control group mean $28.38 \pm$ SD 8.91), 3.) adenoidal-nasopharyngeal ratio ($p = 0.05$).

Cephalometric evaluation of adenoids revealed considerable enlargement of this in mouth-breather children, meanwhile upper airway constriction will appear in the same group. Depth of the palatum will increase when breathing pattern is modified.

Keywords: adenoids, upper airway, mouth breathing, cephalometric.

Introduction

Among mouth breathing etiological factors, adenoids, as hypertrophic lymphatic tissue, are the most frequent cause [1]. By modifying the respiratory patterns, adenoids will determine changes in growth and development of skeletal structures, position of the tongue, jaws, and morphological and functional changes will occur and “adenoid face” will appear [2]. This typical arrangement of the whole face result narrow upper and lower arch, lateral cross-bite and, retrognathic and clockwise rotation of the mandible and increase lower facial height will appear [3].

The most reliable diagnostic tool for mouth breathing caused by adenoids is still a matter of debate, ENT examination methods (nasal endoscopy) seem to be a quite reliable method. To refer pediatric patients for further ENT examinations, cephalometric analysis may provide valuable information regarding upper airway obstructions [4].

During cephalometric analysis before orthodontic treatment, orthodontist should

also analyze the soft tissues, so cephalometric analysis of tonsils and adenoids can be easily included in this matter. Upper airway can be easily identified, and intraoral soft tissues (tongue, adenoids, tonsils) as well as related structures are visible on a well-executed lateral X-ray.

To be able to quantify the changes in the posterior airway and adenoids as well, many measurement methods were used. It seems so far, that Fujioka's adenoid-nasopharyngeal ratio [5] is considered one of the most reliable methods for adenoid size evaluation.

By this retrospective analysis, our purpose was to investigate whether there are any differences in the growth direction between patients with adenoids caused mouth breathing and matched controls. We also would like to describe the association between posterior airway constriction and bone development patterns, to underline the importance of a complex cephalometric analysis prior orthodontic treatment and the benefits of this

method to consider a proper etiological treatment.

Material and methods

Our retrospective data was obtained from Department of Orthodontics, Faculty of Dental Medicine, George Emil Palade University of Medicine, Pharmacy, Science, and Technology of Târgu Mureş. 30 patients were selected from our digital database for our study, 17 boys and 13 girls, age 10.8 ± 1.2 . Each studied case was mouth breather, and was referred for ENT examination, which revealed hypertrophy of adenoids. From the same database we assigned for control group, 30 patients with normal breathing pattern, 17 boys and 13 girls, age 11.1 ± 0.9 . All studied individuals were referred to orthodontic treatment between March 2019 – February 2020. Approval of the Ethics Committee of the Scientific Research of our university was obtained (Decision nr. 1836/21.07.2022.), and every patient's tutor signed its' approval to conduct this study.

On each lateral X-ray, using the ImagePro-InSight computerized morphometric soft, we recorded well-defined cephalometric points to determine the size of the adenoids, the depth of the palate and the position of the tongue.

Data was collected in Excel-file for both groups, and after filtering out the outliers in GraphPad-InStat system, statistical analysis was performed.

For the measurement of nasopharyngeal lymphoid tissues, we selected three well-defined points:

1. The deepest point of the Sella (S)
2. The greatest convexity of the adenoid vegetation (A)
3. The upper posterior point of the hard palate (P).

By connecting the three above mentioned cephalometric points, we measured three linear distances:

1. SA, the distance between Sella and adenoid vegetation
2. SP, the distance between Sella and palatum
3. AP, which meant the distance between adenoid vegetation and palate.

After measuring the three above mentioned distances for every patient, adenoidal-

nasopharyngeal ratio described by Fujioka et al. was also determined. The adenoidal/nasopharyngeal (A/N) ratio was calculated by division of the distance between the maximal convexity of adenoid shadow and spheno-basio-occipital synchondrosis (A) by the distance between spheno-basio-occipital synchondrosis and posterior/superior edge of the hard palate (N) [6]. By this ratio, we divided the control group in three sub-groups and colored them differently in our Excel file:

1. Normal size adenoids (range 0.499-0.621)
2. Moderately increased adenoids (range 0.652-0.724)
3. Strongly increased adenoids (range 0.732-0.853).

To measure the depth of the palatum, we first had to determine the base of the maxilla, marked by a line defined by the spina nasalis anterior (SpNant) and the spina nasalis posterior (SpNpost). The second line was the one which was traced between the enamel-cementum junction of the upper central incisor and the same junction of the upper first permanent molar (ICV-M6). A P' perpendicular was traced between the two lines at the level of the first and second bicuspid interdental contact point (maximum palatum concavity), which would show the depth of the palate.

The position of the tongue was measured using a triangle defined by Bibby and Preston [7]. The three points required to define a triangle are:

1. C3, which is the lowest point of the third cervical vertebra.
2. H (Hyoidale) which is the uppermost, foremost point of the body of the lingual bone.
3. RGN (Retrognathion) which is the lowest posterior point of the symphysis.

Furthermore, the perpendicular drawn from the H point to the line C3-RGN gives the position of the tongue in the vertical plane and was marked by H' [8].

To evaluate the position of the tongue to the mandible, we traced a perpendicular (H'') from the uppermost point of the hyoid bone to the base of the mandible.

After recording the points, the linear measurements were done using the ImagePro-

Insight soft, and data was collected in separate Excel files for study and control group. The

measurements applied in our study can be found in Figure 1.

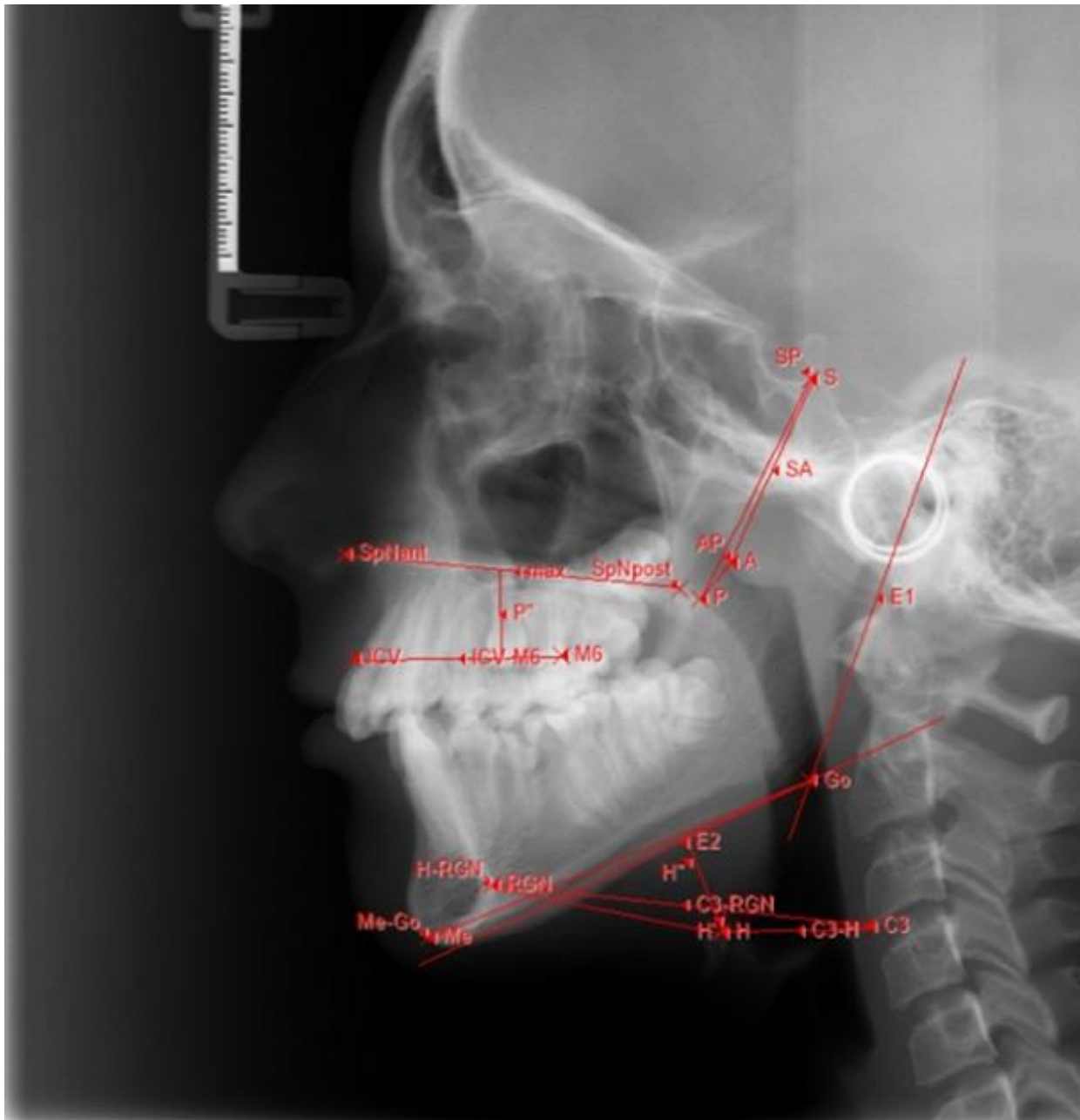


Figure 1. Measurements applied in our study

Statistical analysis

First, outliers were filtered out for both groups, using the Grubbs Test. Descriptive statistics was performed (GraphPad-InStat) mean values, standard deviation (\pm SD), and minimum and maximum values for each group were defined. Using the Kolmogorov-Smirnov normality study, we found the normal distribution of the values according to the Gaussian curve. This was followed by analytical statistics, during which we searched

for significant differences between the two groups using an unparallelled T-test ($p < 0.05$).

Results

When adenoids have been measured, several values differed significantly regarding the size of adenoid vegetation. When measuring the distance between adenoid vegetation and the palate (AP), this value was significantly lower in mouth breathers (mean

9.76 ± SD 3.04) compared to the control group (mean 14.38 ± SD 4.41). When analyzing the distance between Sella and the adenoids (SA), the data of the study group (mean 33.39 ± SD 4.39) were significantly higher ($p = 0.001$) compared to the control group (mean 28.38 ± SD 8.91). Examining the distance between Sella and the posterior point of the palate, we found no significant difference ($p = 1.31$) between the values measured in the mouth breathers (mean 42.64 ± SD 2.66) and those found in the control group (mean 39.38 ± SD 7.69).

Examining Fujioka's ratio, we found a significant difference between the two groups ($p = 0.05$). All patients selected in the study group (mean value for A/N ratio 0.78 ± SD 0.79) had strongly increased adenoid vegetation by Fujioka classification (mean 0.726 ± SD 0.1007). The 0.65 ± SD 0.14 mean found in the control group corresponded to the slightly increased adenoid vegetation group (mean 0.680 ± SD 0.1028).

Examination of the depth of the palate, denoted by P', revealed a statistically significant difference between the two groups ($p = 0.18$): control group – mean 11.58 ± SD 2.48., study group - mean 13.94 ± SD 3.05.

By comparison of the values of ICV-M6 line for the two groups significant difference was found ($p = 0.0001$): study group - mean 36.01 ± SD 1.51, control group - mean 30.15 ± SD 3.36.

Examining the base of the maxilla (SpNant-SpNpost), we found no significant difference between the mean value of 53.26 ± SD 5.11 measured in the mouth breather group and the mean value of 54.81 ± SD 6.61 measured in the control group.

No significant differences have been found between the two groups in the assessment of the tongue position. The distances between the points taken to determine the position of the hyoid bone did not give significant differences. H'' distance had the mean value of 11.45 ± SD 6.72 for mouth breathers and 13.34 ± SD 4.94 for the control group ($p = 3.35$). The mean value for the C3-RGN distance in the study group was 63.97 ± SD 10.4, and for the control group was 62.90 ± SD 8.24 ($p = 7.45$).

The position of the tongue in the vertical plane was defined by the H' distance. The mean value obtained for oral breathers was 3.4 ± SD 2.32, and the mean value for the control group was 4.45 ± SD 2.67 ($p = 2.43$).

The mean distance between C3-H points was 27.64 ± SD 4.08 in the mouth breather group and 27.94 ± SD 5.29 in the control group ($p = 8.85$). Also, the mean value of the lengths of the lines determined by H-RGN was 38.93 ± SD 10.39 in children with oral breathing, and the mean value measured for the control group was 36.48 ± SD 4.77 ($p = 3.36$).

Limitation of the study

Regarding the number of included cases, analysis of more cases should be performed.

Discussions

Many studies aimed to reveal the usefulness of lateral cephalometric analysis as diagnostic tools for the detection of upper airway obstruction due to adenoid hypertrophy [9], but scientific literature seems to be diverse and controversial [10].

When comparing radiological and endoscopic evaluation of the adenoids, both radiographic measurements and nasal endoscopy findings correlate well with the findings of the intra-operative mirror nasopharyngeal exam [11].

Studies, which consider lateral neck X-ray as not so reliable diagnostic tool for adenoid hypertrophy, reveal that while A/N ratio on lateral neck X-ray frequently correlates with adenoid size, lateral neck films can be influenced by patient positioning and involve radiation exposure [12].

Two out of the three methods of adenoid assessment tools are available for orthodontists as well. Clinical signs (rhinorrea, mouth breathing or sleep disorders) can be noticed during clinical examination, lateral cephalometric analysis can reveal the presence of this lymphatic tissue conglomerate and if both examinations are positive, children should be referred for complex ENT examination [13].

Although no universal guidelines for assessing adenoidal enlargement and upper airway obstruction have been established, the

meta-analysis performed by Duan et al. to assess the diagnostic accuracy of a lateral cephalogram for adenoid hypertrophy concluded, that this type of radiological investigation exhibits a very good diagnostic accuracy for the diagnosis of adenoid hypertrophy and posterior upper airway obstruction [14].

Our purpose was to encourage more complex cephalometric analysis prior orthodontic treatment, so where the doubt of adenoids and subsequent mouth breathing occurs, ENT examination should be performed. The age of the analyzed cases was around mixed dentition, and, in some cases, endoscopic examination can be difficult for children at this age.

Guided by these evidence-based findings, we conducted a geometric morphometric study, with no mathematical formulae available, this is the reason why we selected according to the availability of the records, and we selected a minimum of 30 specimen/group [15]. We selected patients referred for orthodontic treatment for 12 months period because of the epidemiological situation during the pandemic, when the ENT diagnosis was difficult to proceed. Morphological measurements conducted in this study describe orthodontic patients, therefore results should be interpreted in this regard, and they should not be applied to the general population.

Upper airway constriction revealed by the AP and SA linear distance measurement as well as Fujioka's A/N ratio showed significant differences between mouth breathers and control group. Our findings revealed enlarged adenoids in the study group and agree with the results of many other studies [16, 17].

Measurements tend to describe palatal morphological changes in mouth breathing cases described a deeper anterior palatum and sagittally elongated upper arch. As oral breathing is the most important etiological factor for constricted maxilla and upper arch, the fact that we were able to describe these alveolar and dental adaptations, concord with several studies [18].

On the contrary, several studies in the literature over the years have demonstrated that there is no regular association between oral

respiration and increased palatal depth [2, 19, 20].

According to our results, during mouth breathing and because of the soft tissue adaptation to this kind of breathing pattern, the perimeter of the upper arch will change, the sagittal elongation is the reflection of upper incisor protrusion [21].

The measurement of the distance defined by us (ICV-M6), traced between the enamel-cementum junction of the upper central incisor and upper first molar, showed a markedly higher value in the mouth-breathing group (mean $36.01 \pm SD 1.15$, $p = 0.0001$). This significant difference shows the backward and downward rotation of the maxilla, and the steep occlusal plane, as compensatory modifications of growth in mouth-breathing children [22].

Due to modified breathing pattern, the hard palatum length will not change, but the vertical and anteroposterior position of the tongue and its relationship to airway size may be more important than soft palate size [23, 24].

Conclusions

Cephalometric evaluation of adenoids revealed considerable enlargement of this in mouth-breather children, meanwhile upper airway constriction will appear in the same group. Depth of the palatum will increase when breathing pattern is modified, but there is no statistical difference regarding the position of the tongue and lingual bone, when results were compared with normal breathing pattern.

Conflict of interest: None to declare.

References

1. Abreu RR, Rocha RL, Lamounier JA, Guerra AF. Etiology, clinical manifestations and concurrent findings in mouth-breathing children. *J Pediatr (Rio J)*. 2008;84(6):529-35.
2. Koca CF, Erdem T, Bayındır T. The effect of adenoid hypertrophy on maxillofacial development: an objective photographic analysis. *J Otolaryngol Head Neck Surg*. 2016;45(1):48.
3. Arsalah R, Waheed H, Fatima J. Cephalometric assessment of patients with adenoidal faces. *J Pak Med Assoc*. 2009;59:747-52.

4. Sarma N, Khaund G. A Comparative Study of Radiograph and Nasal Endoscopy in Diagnosis of Hypertrophied Adenoids. *Indian J Otolaryngol Head Neck Surg.* 2019;71(Suppl 3):1793-1795.
5. Fujioka M, Young LW, Girdany B. Radiographic evaluation of adenoidal size in children: adenoidal-nasopharyngeal ratio. *American Journal of Roentgenology.* 1979;133(3):401-404.
6. Wang J, Zhao Y, Yang W. Correlations between obstructive sleep apnea and adenotonsillar hypertrophy in children of different weight status. *Sci Rep.* 2019;(9):11455.
7. Bibby RE, Preston CB. The hyoid triangle. *Am J Orthod.* 1981; 80:92-7.
8. Hwang S, Chung CJ, Choi YJ, Huh JK, Kim KH. Changes of hyoid, tongue and pharyngeal airway after mandibular setback surgery by intraoral vertical ramus osteotomy. *The Angle Orthodontist.* 2010;80(2):302-308.
9. Soldatova L, Otero HJ, Saul DA, Barrera CA, Elden L. Lateral Neck Radiography in Preoperative Evaluation of Adenoid Hypertrophy. *Annals of Otolaryngology, Rhinology & Laryngology.* 2020;129(5):482-488.
10. Feres MF, Hermann JS, Cappellette M Jr, Pignatari SS. Lateral X-ray view of the skull for the diagnosis of adenoid hypertrophy: a systematic review. *Int J Pediatr Otorhinolaryngol.* 2011;75(1):1-11.
11. Lertsburapa K, Schroeder JW Jr, Sullivan C. Assessment of adenoid size: A comparison of lateral radiographic measurements, radiologist assessment, and nasal endoscopy. *Int J Pediatr Otorhinolaryngol.* 2010;74(11):1281-5.
12. Baldassari CM, Choi S. Assessing adenoid hypertrophy in children: X-ray or nasal endoscopy? *Laryngoscope.* 2014;124(7):1509-1510.
13. Hanzhong D, Li X, Wangfang H, Yongdong L, Zhihui L, Qing L. Accuracy of lateral cephalogram for diagnosis of adenoid hypertrophy and posterior upper airway obstruction: A meta-analysis. *Int J of Pediatr Otorhinolaryngol.* 2019;(119):1-9.
14. Duan H, Xia L, He W, Lin Y, Lu Z, Lan Q. Accuracy of lateral cephalogram for diagnosis of adenoid hypertrophy and posterior upper airway obstruction: a meta-analysis. *Int J Pediatr Otorhinolaryngol.* 2019;119:1-9.
15. Cardini A, Elton S. Sample size and sampling error in geometric morphometric studies of size and shape. *Zoomorphology.* 2007;(126):121-134.
16. Murilo FN, Helder IP, Sheila MF, Shirley SN. Reliability of radiographic parameters in adenoid evaluation. *Braz J Otorhinolaryngol.* 2012; 78(4):80-90.
17. Yueniwati Y, Halim N. Diagnostic Test Value of Assessment Adenoid Enlargement with and Without Airway Obstruction Using Lateral Soft Tissues X-ray Compared to Nasoendoscopy. *Indian J Otolaryngol Head Neck Surg.* 2019;(71):1739-1744.
18. Raffat A, Hamid W. Cephalometric assessment of patients with adenoidal faces. *J Pak Med Assoc.* 2009;59(11):747-52.
19. Vig KW. Nasal obstruction and facial growth: the strength of evidence for clinical assumptions. *Am J Orthod Dentofacial Orthop.* 1998;113(6):603-611.
20. Fields HW, Warren DW, Black K, Phillips C. Relationship between vertical dentofacial morphology and respiration in adolescents. *Am J Orthod Dentofacial Orthop.* 1991;99(2):147-154.
21. Lione R, Franchi L, Ghislanzoni LTH, Primozic J, Buongiorno M, Cozza P. Palatal surface and volume in mouth-breathing subjects evaluated with three-dimensional analysis of digital dental casts—a controlled study. *Eur J Orthod.* 2015;37(1):101-104.
22. Zhao Z, Zheng L, Huang X. Effects of mouth breathing on facial skeletal development in children: a systematic review and meta-analysis. *BMC Oral Health* 2021;21:108.
23. Pae EK, Lowe AA, Sasaki K, Price C, Tsuchiya M, Fleetham JA. A cephalometric and electromyographic study of upper airway structures in the upright and supine positions. *Am J Orthod Dentofacial Orthop.* 1994;106(1):52-9.
24. Linder-Aronson S, Leighton BC. A longitudinal study of the development of the posterior nasopharyngeal wall between 3 and 16 years of age. *Eur J Orthod.* 1983;5:47-58.

Corresponding author:

Krisztina Martha

George Emil Palade University of Medicine, Pharmacy, Science and Technology of Târgu Mureș, 38 Gheorghe Marinescu street, Târgu Mureș, 540139, Romania

Email: krisztina.martha@umfst.ro

Received: July 27, 2022 / Accepted: September 9, 2022