

ORIGINAL RESEARCH

DOI: 10.62838/ASMJ.2024.2.02

Periodontal soft tissue changes observed during orthodontic treatment with conventional metal fixed appliances.

Bădărău-Șuster Andrei-Mario¹, Zamfir Anca-Georgiana¹, Vlasa Alexandru¹, Coman Tatiana-Maria¹

¹ George Emil Palade University of Medicine, Pharmacy, Science, and Technology of Târgu-Mureș, Romania

Abstract

Introduction: We are currently seeing an increase in the number of patients seeking orthodontic treatment, many of whom are young adults. Besides the obvious advantages of orthodontic therapy, there are also some side effects that can be seen at the level of periodontal soft tissues, which can influence the final result. **Aim of the study:** The purpose of this study is to identify the main changes observed in the soft tissues during orthodontic treatment with fixed appliances (colour, size, position, texture of gingiva and shape of anterior interdental papillae), and to analyse them depending on individual clinical characteristics, gender and gingival phenotype. **Material and Methods:** 22 patients were included in this study – 12 women and 10 men, aged between 14 and 30 years, that presented to the Integrated Centre of Dental Medicine in Târgu Mureș, in the period 2019-2024, in search of orthodontic treatment. **Results:** The study found significant differences in gingival changes based on gender and gingival phenotype, with females showing more pronounced colour changes and gingival hypertrophy in the mandibular regions, and males exhibiting substantial gingival hypertrophy and colour changes, both in the frontal and lateral maxillary regions. **Conclusions:** This study shows gingival changes during orthodontic treatment that differ by gender and gingival phenotype. Thus, females with a thick gingival phenotype show distinct colour and size changes in the frontal mandibular region, whereas male patients tend to have more changes in the frontal and lateral maxillary regions, regardless of the gingival phenotype.

Keywords: gingival changes, orthodontic treatment, gingival phenotype.

Introduction

In recent years, following the advances in the field of Dentistry, there has been a notable increase in the number of patients undergoing orthodontic treatment [1–5]. As a result, there is a heightened recognition of the role that optimal occlusion plays in preserving the integrity of the entire stomatognathic system. Even if, traditionally orthodontic treatment was mostly associated with the adolescent population, while adult patients frequently opted for fixed prosthetic solutions to correct malocclusion, nowadays, there is a growing trend of adults seeking orthodontic care.

Orthodontic treatment enhances patients' quality of life by correcting dental alignment or guiding dento-maxillary development, leading to improvements such as increased masticatory efficiency, optimized temporomandibular joint function, corrected pronunciation and improved facial appearance. In addition, by facilitating oral hygiene after orthodontic therapy there is a decrease in the incidence of interdental caries and by correctly aligning

teeth on the arch it helps prevent gingivitis and periodontitis. Patients who have undergone orthodontic treatment experience greater self-confidence and a reduction in psychological distress related to physical appearance, so orthodontic treatment has also been observed to have a positive impact on people's psychological well-being [6].

Given the long-term nature of orthodontic therapy, fixed appliances have potential risks, complications and side effects, so it can have a significant impact on periodontal status, with effects manifested as soft tissues changes, including variations of colour, gingival hyperplasia or hypertrophy, changes in the shape of interdental papillae, displacement of the gingival margin, and modifications in the surface texture of gingival tissue [7–9].

Fixed orthodontic treatment makes oral hygiene difficult, creating conditions for the accumulation of bacterial plaque. This biofilm accumulation on tooth surfaces favors the installation of gingivitis and if it is not kept

under control, gingival hyperplasia or gingival recessions may eventually occur [7].

Gingivitis is clinically expressed by changes in colour, the disappearance of gingival stippling and the increase in tissue volume. Orthodontic movement does not directly cause gingivitis, but the presence of bacterial plaque does [10].

Gingival hypertrophy is another side effect that occurs in orthodontic treatment and consists in increasing the volume of the cells, without changing their number. On the other hand, gingival hyperplasia represents the increase in the number of cells, which have a normal volume. Due to the fact that gingival hypertrophy also occurs in patients with good oral hygiene, it is believed that the orthodontic force and tissue remodelling itself are the determining factors of it, through the increase of metalloproteinases in the matrix. Also, it appears that the Nickel ions constantly released from some orthodontic appliances can stimulate the development of epithelial cells and the division of keratinocytes, which could cause gingival hyperplasia or gingival hypertrophy [1, 7].

Changes in the gingival margin position can be observed during orthodontic movements. Thus, an oral movement of the teeth increases the thickness of the gingival tissue at the buccal level and the incisal migration of the gingival margin. In contrast, a movement of teeth towards buccal, translates into cervical migration of the gingival margin [11].

By means of the orthodontic movement of mispositioned teeth, the interdental contact point will be changed. The interdental contact is a very important parameter in determining the height and shape of the interdental papilla. Thus, both in the case of the closing of the diastema and the protrusion of lingualized or superimposed teeth, the size of the interdental papilla will decrease. In contrast, following the retrusion of vestibularized or superimposed teeth and the intrusion of teeth, the papilla will increase in size [12]. Thus, through all the changes described above, we can emphasize the importance of the changes in the superficial

periodontium during the orthodontic treatment.

The aim of this paper is to identify and highlight the variations observed in periodontal soft tissues during treatment with fixed orthodontic appliances and to determine where they preferentially occur according to gingival phenotype and gender.

The null hypothesis of this study is that there is no difference in soft tissue response during orthodontic treatment according to gender and gingival phenotype.

Material and methods

This is a retrospective study that was conducted on a sample of 22 patients (12 female patients and 10 male patients, aged between 14 and 30 years), whose digital intraoral photographs were analysed in order to test the null hypothesis. The case files belonged to previous patients that presented themselves at the Integrated Centre of Dental Medicine in Târgu Mureş for orthodontic treatment in the period 2019-2024. To obtain digital intraoral photographs, we contacted several residents in Orthodontics and Dentofacial Orthopedics and requested photographs from their orthodontic cases documenting the clinical situation of patients who presented various periodontal soft tissues changes during orthodontic treatment. Two time points were established for analysis: T1, which corresponds to the clinical situation before the initiation of orthodontic treatment or the initial bonding session, and T2, any other appliance adjustment appointment, during which the clinician observed periodontal soft tissues changes, regardless of their type (colour, dimension, shape, texture, position), or of period of time since the beginning of the treatment.

Patients, respectively parents/guardians were informed about the possibility of using their information, personal data and digital clinical photographs for future academic and scientific purposes and gave their informed consent.

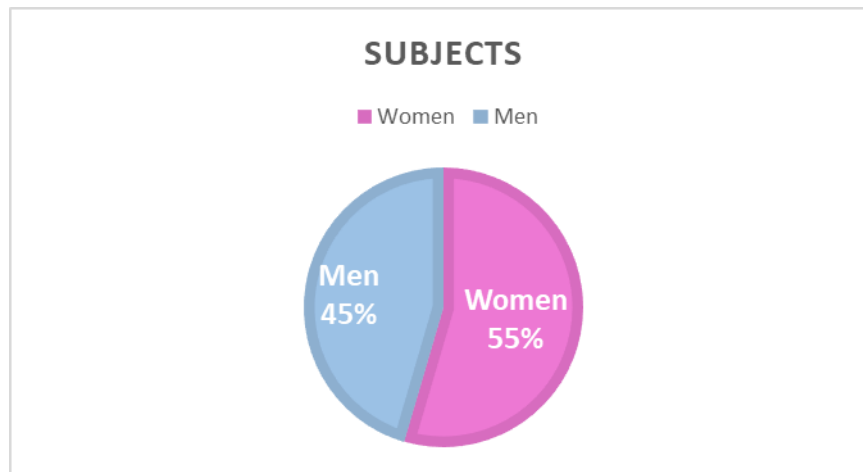


Figure 1. The division of subjects according to gender

Patient Selection Criteria:

1. Patients that presented dento-maxillary anomalies;
2. Patients with orthodontic appliances, whose initial conditions are documented through intraoral photographs;
3. Patients undergoing fixed orthodontic treatment on both dental arches;
4. Patients with orthodontic appliances with metal brackets;
5. Patients with no prior history of orthodontic treatment;
6. Patients without any systemic conditions.

Patient Exclusion Criteria:

1. Patients with systemic conditions affecting periodontal tissues;
2. Patients undergoing chronic treatment with medications that may impact periodontal tissues or their response to orthodontic treatment;
3. Patients receiving orthodontic treatment on only one dental arch;
4. Patients receiving orthodontic treatment with removable orthodontic appliances;
5. Patients whose initial condition is not documented by intraoral digital photographs;
6. Patients with a history of orthodontic treatment.

In addition, we requested further information to conduct the statistical analysis, including sex, age, date of initiation of orthodontic therapy (T1), and the date when changes were observed (T2). Intraoral images were captured using either personal phone cameras or professional cameras.

After analysing and sorting the received digital intraoral photographs of previous patients, we were able to select 22 patients who met the above criteria. In the study were included the patients whose initial periodontal condition was either healthy or showed varying degrees of inflammation due to teeth misalignment, crowding or poor oral hygiene, but who, after a period of time under orthodontic treatment, showed improvement or worsening of soft tissue status.

All intraoral digital photographs, along with the corresponding data for each patient, were inserted into Microsoft® Word (Microsoft®, Redmond, US) for Mac, Version 16.84 (2024). They were organized into individual clinical cases, numbered, and arranged in random order.

During the visual analysis of these digital images, we observed the main changes that occurred in the soft periodontal tissues concerning colour, size, shape of the interdental papilla (in the anterior region), surface texture and the position of the gingival margin. In order to facilitate the process of visual analysis of the photos, we made for each case a collage consisting of two intraoral photos placed vertically, the upper one

corresponding to the initial situation at T1, and the lower one for the situation given at T2.

We systematically recorded for each case in a table the variable clinical aspects observed in the analysed intraoral photographs, according to the dental unit in which they were observed, to facilitate their use in statistical analysis.

To simplify the working method, we have chosen symbols for each change recorded in the table, according to the following legend:

- yes/no = presence or absence of colour changes;
- (+/-) = gingival hypertrophy or absence of changes;
- (\wedge / \vee / u / $_$) = enlargement of dental papilla / decreased in size / invaginated papilla / flat papilla;
- (.../Ø) = stippled gingival texture / no stippling;
- (\uparrow / \downarrow /0) = coronal placement of the gingival margin / apical placement of the gingival margin / no significant changes;
- X = missing tooth [1].

To determine if there were changes in the colour of the gingival tissues, we visually analysed the photos from the two time points. If the gingival tissue seen in the initial situation was coral pink and in the second photo it was bright red, we considered it a shift in colour and noted "yes" in the table. We also looked for colour variations from red to normal colour of gingiva, and we noted them in the table with "yes" as well. If there was no obvious change in soft tissue colour, we noted "no" in the table.

To determine the changes in size, we conducted a comparative visual analysis of the photos at the two time points, T1 and T2, focusing specifically on the interdental gingival tissue and the area between the free gingival margin and the base of the gingival groove. If in any of the previously mentioned regions we observed an increase in tissue, we considered it to be gingival hypertrophy and it was recorded in the table with the symbol "+" symbol, while the absence of changes in size was noted with ".".

The shape of the interdental papillae was evaluated exclusively in the anterior region, due to its significant aesthetic impact on the appearance of the smile. We looked for

variations such as increases or decreases in size, invagination, or flattening of the papillae, which were influenced by the orthodontic movement of adjacent teeth. We considered as an increase in its size the papilla that appeared bigger and more globulos than in the initial situation, and a decrease, if the papilla was thinner and smaller. The invagination of the papilla was observed in photographs at T2 as an internal fold of the excessive tissue, while the flat papilla appeared as a horizontal gingival tissue between two adjacent teeth, losing its pyramidal shape.

In terms of surface texture of the periodontium, we observed the loss of its orange peel appearance. This was identified by close examination and enlarging the digital photographs using the zoom function in Word. If the gingiva appeared smooth or spongy, with punctate insertions of Sharpey's fibres no longer visible, we considered it as a loss of texture and noted it with "Ø" in the table.

For changes in the position of the free gingival margin in the incisal/occlusal or apical direction, we looked at the size of the clinical crown, at both T1 and T2, and tried to visually estimate whether there was any change in crown dimensions. We used the " \uparrow " symbol to indicate a decrease in crown size, the " \downarrow " symbol for an increase, and "0" where there were no visible changes in size.

We established the gingival phenotype of the patients by visual examination of the intraoral images, according to the buccal appearance of the alveolar process in the frontal group area, depending on the degree of visibility of the underlying capillary vessels, correlating with the shape of the teeth, thus placing it in two categories: thick and thin.

After analysing all the intraoral images, we obtained 22 tables, that illustrate the changes in the periodontal soft tissues, categorized by each tooth, from 1.6 to 4.6, with separate tables for the upper and lower dental arches. Then, the acquired data was transferred into the Microsoft® Excel (Microsoft®, Redmond, US) for Mac, Version 16.84 of 2024, to conduct the statistical analysis.

To assess differences in periodontal soft tissue changes during orthodontic treatment, we performed a Chi-square test of

independence. The analysis included four variables: colour change, size change, texture change, and position change of the gingival margin. These changes were observed in two regions: frontal (F) and lateral (L), for both the maxillary and mandibular arches. The patients were classified by gender (male, female) and gingival phenotype (thick, thin).

For the analysis a contingency table was constructed for each variable based on the observed frequencies of changes according to gender, gingival phenotype, and region (frontal and lateral).

Chi-square tests were applied to assess whether the differences in these changes were statistically significant across the groups.

The analysis excluded lateral regions for shape changes, as the study focused exclusively on the frontal regions for this variable. The invagination (U) category was excluded from the analysis due to its low frequency of occurrence, which would result in statistical limitations in the Chi-square test.

The significance threshold for all tests was set at $p < 0.05$.

Results

This study examined the variations in soft tissue characteristics, including colour, size, surface texture and position of the gingival

tissue alongside with the shape of the anterior interdental papillae, across different genders and gingival phenotypes. The findings reveal significant patterns and differences, reflecting the complexity and diversity of gingival response to the orthodontic tooth movement.

Colour Changes

Colour changes in the gingiva varied between genders and gingival phenotypes. Among females that presented a thick gingival phenotype, the mandibular frontal region exhibited the most pronounced colour changes, with 83.3% of cases showing changes in colour. In contrast, the mandibular lateral region displayed minimal changes, with only 12% showing any difference. Women with a thin gingival phenotype showed a remarkable 94.4% colour change in the mandibular frontal region. No changes were observed in the maxillary lateral region.

For males, those with a thick gingival phenotype exhibited the highest colour changes in the maxillary frontal region at 93.1%, while the mandibular frontal region had a moderate change rate of 66.6%. The Chi-square test for colour changes across gender and gingival phenotype yielded significant results ($\chi^2(9) = 142.14$, $p < 0.001$), indicating that colour changes were significantly associated with gender and gingival phenotype.

Table 1. Colour changes

Gender	Gingival Phenotype	Maxillary F (%)	Maxillary L (%)	Mandible F (%)	Mandible L (%)
Female	Thick	53.7	30.7	83.3	12
Female	Thin	22.2	0	94.4	16.6
Male	Thick	93.1	46.4	66.6	21.4
Male	Thin	60	60.7	23.3	14.8

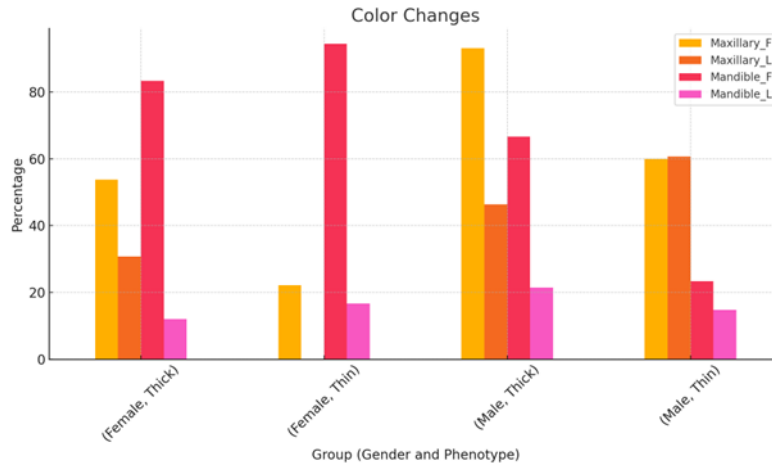


Figure 2. Colour changes

Size Changes

Gingival hypertrophy, as indicated by size changes, also displayed distinct trends across different groups. Females with a thick phenotype had the highest hypertrophy rate in the mandibular frontal region (83.3%), whereas the maxillary lateral region showed a lower one (44.2%). However, women with a thin phenotype had consistently high hypertrophy rates in both the maxillary and mandibular frontal regions, at 61.1% and 83.3%, respectively.

Among men with a thick gingival phenotype, it was observed a significant hypertrophy in the maxillary frontal region (79.3%), while the mandibular lateral region showed the least hypertrophy (28.5%). Males with a thin phenotype exhibited the most substantial hypertrophy in the mandibular frontal region, where every case (100%) showed signs of enlargement. A significant association was found between size changes, gingival phenotype and gender ($\chi^2(9) = 40.06$, $p < 0.001$).

Table 2. Size changes

Gender	Gingival Phenotype	Maxillary F (%)	Maxillary L (%)	Mandible F (%)	Mandible L (%)
Female	Thick	74	44.2	83.3	46
Female	Thin	61.1	27.7	83.3	22.2
Male	Thick	79.3	53.5	76.6	28.5
Male	Thin	63.3	60.7	100	81.4

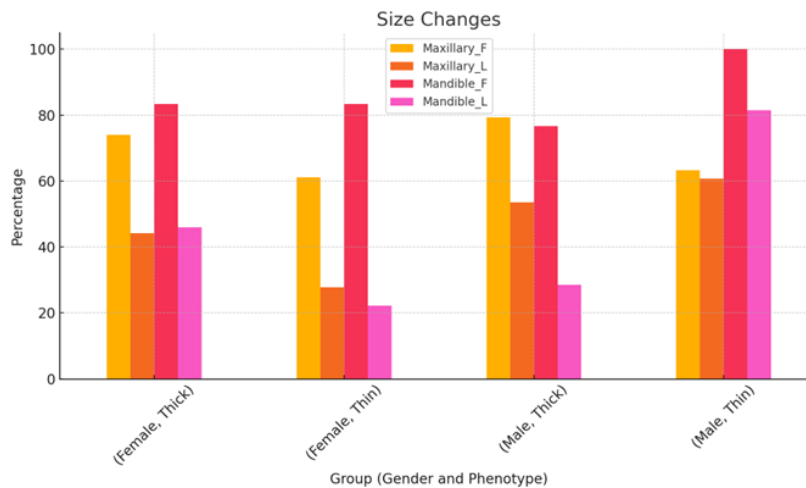


Figure 3. Size changes

Shape Changes (Frontal Group Only)

Examining shape changes in the frontal group provided insights into how different gingival phenotypes and genders affect gingival morphology. A thick phenotype at females was associated with an enlargement of the dental papilla, in both the maxillary and mandibular regions, at 71.1% each. On the other hand, women that presented a thin phenotype, primarily showed decreased size of the dental papilla in the maxillary region (53.3%), reflecting a different response pattern.

It was observed a significant papilla enlargement in the mandibular region for men

with a thick gingival phenotype, with a percentage of 84% and a notable incidence of flat papilla in the maxillary region (8.3%). Males with a thin phenotype displayed uniform enlargement in the mandibular region (100%) and an equal distribution of enlargement and reduction in the maxillary region (48% each). After excluding the "U" category from the analysis, the remaining data still showed significant differences between gender, phenotype, and changes in the shape of the interdental papillae ($\chi^2(15) = 126.24, p < 0.001$).

Table 3. Shape changes

Gender	Gingival Phenotype	Maxillary Λ (%)	Maxillary V (%)	Maxillary U (%)	Maxillary _ (%)	Mandibl e Λ (%)	Mandibl e V (%)	Mandibl e U (%)	Mandibl e _ (%)
Female	Thick	71.1	15.5	4.4	8.8	71.1	26.6	0	2.2
Female	Thin	46.6	53.3	0	0	66.6	33.3	0	0
Male	Thick	45.8	41.6	4.1	8.3	84	4	0	12
Male	Thin	48	48	0	4	100	0	0	0

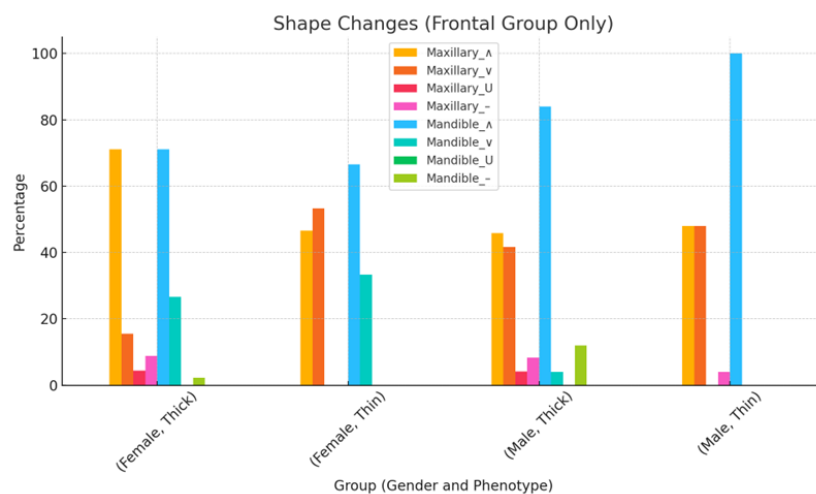


Figure 4. Shape changes

Texture Changes

Texture changes, characterized by the absence of stippling, were also examined. Females with a thick phenotype exhibited the highest absence of stippling texture in the mandibular lateral region (84%), with the least value in the maxillary frontal region (29.6%). For females with a thin phenotype, both the maxillary and mandibular lateral regions

showed a complete absence of stippling (100%).

Among males, those with a thick phenotype displayed a complete absence of stippling in the mandibular lateral region (100%), with significant changes noted across the maxillary regions. Males with a thin phenotype showed pronounced texture changes, particularly in the mandibular

lateral region (92.5%). The Chi-square test for texture changes also indicated a significant relationship between gender, phenotype and

the texture of the gingiva ($\chi^2(9) = 20.89, p = 0.013$).

Table 4. Texture changes

Gender	Gingival Phenotype	Group	Maxillary F (%)	Maxillary L (%)	Mandible F (%)	Mandible L (%)
Female	Thick	F	29.6	50	66.6	84
Female	Thin	L	33.3	100	66.6	100
Male	Thick	F	48.2	78.5	80	100
Male	Thin	L	26.6	85.7	46.6	92.5

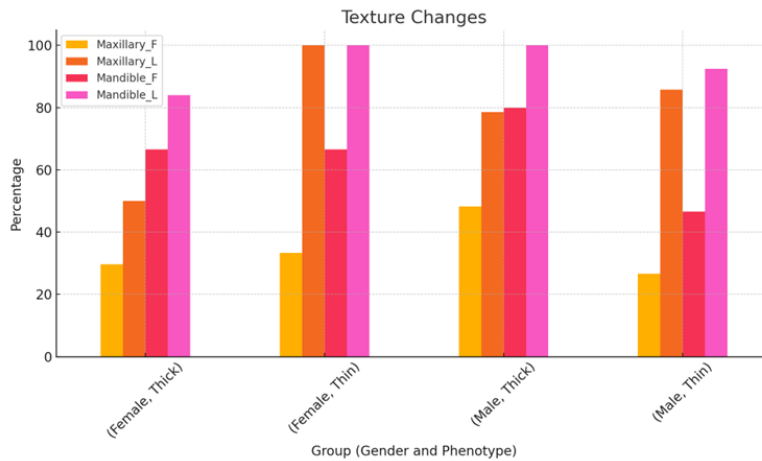


Figure 5. Texture changes

Position Changes of the Gingival Margin

The analysis of position changes in the gingival margin revealed diverse patterns of coronal and apical movement. Females with a thick phenotype predominantly exhibited a rate of coronal placement in the maxillary frontal region (81.4%) and mandibular frontal region (70.3%). It was observed a mix of coronal and apical movements at females with a thin phenotype, with moderate rate of coronal placement in the maxillary frontal region (61.1%).

For males with a thick phenotype, both coronal and apical placements were observed, particularly in the mandibular regions, where coronal and apical placements were noted in nearly equal proportions (43.3% coronal, 33.3% apical). Males with a thin phenotype had a higher percentage of coronal placement in the mandibular frontal region (66.6%), indicating a preference for movement in this direction. The Chi-square test showed a significant association between position changes and the independent variables ($\chi^2(21) = 174.64, p < 0.001$).

Table 5. Position changes of gingival margin

Gender	Gingival Phenotype	Group	Maxillary ↑ (%)	Maxillary ↓ (%)	Mandible ↑ (%)	Mandible ↓ (%)
Female	Thick	F	81.4	0	70.3	18.5
Female	Thick	L	50	0	48	6
Female	Thin	F	61.1	11.1	38.8	22.2
Female	Thin	L	22.2	0	22.2	5.5
Male	Thick	F	68.9	6.8	43.3	33.3
Male	Thick	L	50	0	25	50
Male	Thin	F	23.3	6.6	66.6	6.6
Male	Thin	L	60.7	3.5	51.8	0

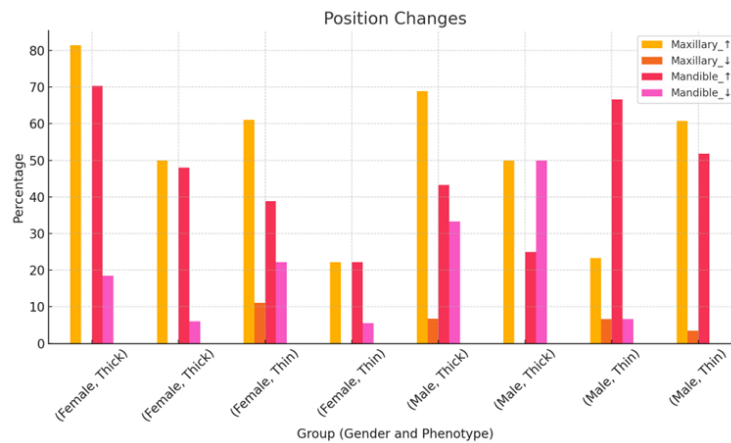


Figure 6. Position changes of gingival margin

Discussions

Overall, the study findings highlight distinct patterns of gingival changes, influenced by gender and gingival phenotype. Males with thin phenotypes tended to exhibit higher rates of gingival hypertrophy and shape changes, while females showed more pronounced colour changes and texture alterations. These results underline the importance of considering both gender and gingival phenotype in understanding gingival responses and planning dental care strategies accordingly.

Colour Changes

One of the findings of this study shows a distinct pattern of colour changes in gingiva between males and females, during orthodontic treatment with fixed appliances. Females, particularly those that presented a thick gingival phenotype, exhibited more pronounced colour changes in the mandibular frontal region, while men with thick phenotype showed colour changes in the maxillary frontal region. This could be due to hormonal activity, that is known to affect gingival tissue, making it prone to inflammatory changes and colour alterations [13–15]. The hormones can modify the immune response of gingival tissues to dental plaque. Also, one study established that gingival inflammation and plaque accumulation are higher during the premenstrual period [16]. We observed more colour changes in the frontal region, in contrast with a literature finding, with a higher percentage of visually inflamed gingival sites in the lateral regions [17].

Size Changes

This study highlighted significant differences in gingival hypertrophy between genders. Women with both thick and thin gingival phenotype showed gingival enlargement, especially in the mandibular frontal region. In the same area, men showed the highest rate of size changes, but it was observed in those with thin phenotype. One study highlighted that a predisposing factor during fixed orthodontic treatment was a thick periodontal phenotype [18].

Shape Changes

When examining shape changes, particularly in the frontal group, there were notable differences between males and females. Women with a thick phenotype displayed enlargement of the dental papilla, whereas men showed more variable responses, with both increases and decreases in papilla size. These findings could reflect differences in how males and females respond to inflammatory stimuli or plaque accumulation. Papillary height and thickness of the papilla base were associated with the gingival phenotype with significant statistical correlations [19].

Texture Changes

Texture changes, characterized by the absence of stippling, were also significant in both genders, but the patterns varied. Women that presented a thin phenotype showed a complete absence of stippling in the maxillary and mandibular lateral regions. Also, men, particularly those with thick phenotype,

revealed complete loss of orange peel texture in the mandibular lateral region. One literature evidence showed that gingival enlargement produces changes in the texture of the gingiva [20].

Position Changes of the Gingival Margin

Higher rates of gingival margin changes were observed in the mandibular regions, at females, where the gingival margin tended to change its position towards the coronal part of the teeth. This coronal movement might protect against recession but could also predispose to pocket formation, if not managed properly. This overgrowth related to orthodontic movement was observed in different studies [18, 21].

The study's findings that women, especially those with a thick gingival phenotype, exhibit more changes in colour and size, suggest that they may be at higher risk for gingival inflammation during orthodontic treatment, especially since the bacterial plaque accumulates much more easily at the level of the brackets. Similarly, males with a thin phenotype, showing more hypertrophy and coronal positioning of the gingival margin, may also be more susceptible to gingival overgrowth and pocket formation during treatment.

This study has several limitations, such as: limited number of patients, different periods of time between the treatment sessions in which the intraoral photographs were taken, the subjective analysis of the photos, which can be influenced by factors like lighting, angle and image quality.

Understanding the long-term effects of fixed appliances on different gingival phenotypes and genders will help clinicians, especially periodontists, in the management of potential periodontal complications during orthodontic tooth movement. This study is also addressed to orthodontists, as it draws attention to the importance of periodontal tissues in the predictability of the treatment outcome and in obtaining adequate final aesthetic results.

Future research should focus on studies that track periodontal changes in patients before, during and after orthodontic treatment. Also, in the upcoming studies, direct observation of

gingival changes is recommended, with the patient in front of the examiner, while the following periodontal indices may also be performed: PPD, CAL, PI, BOP.

Conclusions

Within the limits of this study, the following conclusions were drawn:

- 1) Orthodontic treatment affects the periodontal soft tissue, causing changes in their colour, size, shape, texture and position;
- 2) The null hypothesis is rejected. A significant association was found between soft tissues changes, gingival phenotype and gender;
- 3) Female patients with thick gingival phenotype showed more pronounced colour and size changes in the frontal mandibular region;
- 4) Male patients, regardless of gingival phenotype, showed changes in soft tissue colour and size in the frontal and lateral maxillary regions.

Conflict of interest: The authors declare no conflicts of interest.

References

1. Zamfir A-G. Modificările țesuturilor parodontale moi în timpul tratamentului cu aparate ortodontice fixe. *Lucrare de Licență. Universitatea de Medicină, Farmacie, Științe și Tehnologie "George Emil Palade" din Târgu Mureș*; 2024.
2. Curto A, Mihit F, Curto D, Albaladejo A. Assessment of Orthodontic Treatment Need and Oral Health-Related Quality of Life in Asthmatic Children Aged 11 to 14 Years Old: A Cross-Sectional Study. *Children*. 2023;10(2):176.
3. Tolessa M, Singel AT, Merga H. Epidemiology of orthodontic treatment need in southwestern Ethiopian children: a cross sectional study using the index of orthodontic treatment need. *BMC Oral Health*. 2020;20(1):210.
4. Mylonopoulou I-M, Sifakakis I, Berdouses E, Kavvadia K, Arapostathis K, Oulis CJ. Orthodontic Status and Orthodontic Treatment Need of 12- and 15-Year-Old Greek Adolescents: A National Pathfinder Survey. *International Journal of Environmental Research and Public Health*. 2021;18(22):11790.
5. Iranzo-Cortés JE, Montiel-Company JM, Bellot-Arcis C, Almerich-Torres T, Almerich-Silla JM. Need for Orthodontic Treatment in Pupils Aged between

- 12 and 15 in the Valencian Region (Spain). *International Journal of Environmental Research and Public Health*. 2021;18(19):10162.
6. Mandava P, Singaraju GS, Obili S, Nettam V, Vatturu S, Erugu S. Impact of self-esteem on the relationship between orthodontic treatment and the oral health-related quality of life in patients after orthodontic treatment - a systematic review. *Med Pharm Rep*. 2021;94(2):158–69.
7. Liu Y, Li CX, Nie J, Mi CB, Li YM. Interactions between Orthodontic Treatment and Gingival Tissue. *Chin J Dent Res*. 2023;26(1):11–8.
8. Jati AS, Furquim LZ, Consolaro A. Gingival recession: its causes and types, and the importance of orthodontic treatment. *Dental Press J Orthod*. 2016;21(3):18–29.
9. Abdelhafez RS, Talib AA, Al-Taani DS. The effect of orthodontic treatment on the periodontium and soft tissue esthetics in adult patients. *Clin Exp Dent Res*. 2022;8(1):410–20.
10. Alsulaimani L, Alqarni H, Akel M, Khalifa F. The Orthodontics-Periodontics Challenges in Integrated Treatment: A Comprehensive Review. *Cureus*. 2023;15(5):e38994.
11. Kandasamy S, Goonewardene M, Tennant M. Changes in interdental papilla heights following alignment of anterior teeth. *Australian orthodontic journal*. 2007;23:16–23.
12. Kim Y-K, Kwon E-Y, Cho Y-J, Lee J-Y, Kim S-J, Choi J. Changes in the vertical position of interdental papillae and interseptal bone following the approximation of anterior teeth. *Int J Periodontics Restorative Dent*. 2014;34(2):219–24.
13. O'Neil TC. Maternal T-lymphocyte response and gingivitis in pregnancy. *J Periodontol*. 1979;50(4):178–84.
14. Boyapati R, Cherukuri SA, Bodduru R, Kiranmaye A. Influence of Female Sex Hormones in Different Stages of Women on Periodontium. *J Midlife Health*. 2021;12(4):263–6.
15. Sathish AK, Varghese J, Fernandes AJ. The Impact of Sex Hormones on the Periodontium During a Woman's Lifetime: a Concise-Review Update. *Curr Oral Health Rep*. 2022;9(4):146–56.
16. Kamal Asaad N, Abbood HM. Comparing gingival inflammation and salivary acidity to hormonal variation during menstruation. *Saudi Dent J*. 2023;35(3):251–4.
17. Polson AM, Subtelny JD, Meitner SW, et al. Long-term periodontal status after orthodontic treatment. *American Journal of Orthodontics and Dentofacial Orthopedics*. 1988;93(1):51–8.
18. Vincent-Bugnas S, Borsa L, Gruss A, Lupi L. Prioritization of predisposing factors of gingival hyperplasia during orthodontic treatment: the role of amount of biofilm. *BMC Oral Health*. 2021;21(1):84.
19. Zhong C, Yingzi X, Zhiqiang L, et al. Analysis of Crown Morphology and Gingival Shape in the Maxillary Anterior Dentition. *Int J Periodontics Restorative Dent*. 2020;40(6):925–31.
20. Georgieva I, Yordanova I. Gingival enlargements. A review. *Varna Medical Forum*. 2020;9(1):99–106.
21. Vijaykumar V, R VK, Archana D, et al. Comparison of the Periodontal Status of Patients Undergoing Labial and Lingual Orthodontic Therapy. *Cureus*. 2020;12(1):e6818.

Corresponding author:

Tatiana-Maria Coman

George Emil Palade University of Medicine, Pharmacy, Science and Technology of Târgu Mureș, 38 Gheorghe Marinescu street, Târgu Mureș, 540139, Romania

Email: tatiana-maria.coman@umfst.ro

Received: August 5, 2024 / Accepted: September 10, 2024