

REVIEW

DOI: 10.62838/ASMJ.2026.2.02

Oral mucosal changes associated with intraoral piercings: a narrative review.

Gabriela GALIT¹, Eugen BUD¹, Andra Elen POPA¹, Adriana Maria MONEA¹¹ George Emil Palade University of Medicine, Pharmacy, Science, and Technology of Târgu-Mureș, Romania

Abstract

Background. Intraoral piercings have been studied for over 50 years, with a primary focus on their impact on oral and overall well-being. As their popularity has grown significantly, understanding the changes that may occur in the oral mucosa following piercings has become an imperative requirement for dentists. Despite numerous studies, a clear, structured synthesis of these mucosal changes is still limited, emphasizing the importance of understanding them in dental practice. **Aim of the study.** The primary objective of this study is to synthesize and systematize the mucosal changes associated with intraoral piercings reported in the specialized literature. Secondary objectives aim to assess the risks that arise according to the locations of oral piercings and, implicitly, to provide an overview of the mucosal defense mechanisms associated with periodontal, hyperplastic, or inflammatory changes in the mucosa. **Methods.** This study is a narrative review that synthesizes existing literature published from the beginning of the 21st century to the present, focusing on the impact of intraoral piercings on the oral mucosa. Relevant English-language publications were identified through PubMed and Google Scholar, using terms such as "intraoral piercing", "oral mucosa", and "oral complications", combined with Boolean operators "AND" and "Or". The reviewed literature included case reports, narrative reviews, cross-sectional studies, systematic and meta-analyses describing oral mucosal changes associated with intraoral piercings. Publications focused exclusively on extraoral piercings or unrelated to oral mucosal changes were not considered relevant for this review. **Results.** Intraoral piercings are consistently associated with trauma to the oral mucosa. Direct effects include inflammatory, hyperplastic, and atrophic changes. Indirect effects involve alterations in hard tissues and the periodontium, such as gingival recession, enamel wear, tooth fractures, and periodontal lesions. **Conclusions.** Intraoral piercings should not be considered merely as cosmetic jewelry but as a genuine risk factor. Understanding the impact of a piercing on the oral mucosa is an indispensable skill for a dentist in current practice, given the increasing number of people wearing oral jewelry and the incidence of mucosal changes.

Keywords: intraoral piercing, oral mucosa, mucosal changes.

Introduction

Permanent body art, such as tattoos and piercings, has always been a subject of interest to society and has been practiced for centuries by various ethnic groups [1,2]. It is fascinating that, although they seem unique to our times, they have a long and remarkable history; their use serves as a tribute to the past. Since the oral cavity also plays an essential role in maintaining the body's overall health, this review will summarize mucosal changes associated with intraoral piercings, as identified in various studies conducted both at the beginning of the millennium and in the most recent findings [3].

Material and methods

This study is a narrative review and aims to analyze articles published in specialized

literature regarding oral complications associated with intraoral piercings, with a focus on mucosal changes. Relevant studies were identified through searches in PubMed and Google Scholar using combinations of the terms "intraoral piercing", "oral mucosa", and "oral complications", connected by the Boolean operators "AND" and "OR". Articles were reviewed for relevance to the topic based on their titles and abstracts, and those addressing oral mucosal changes associated with intraoral piercings were considered for inclusion. The identified literature included case reports, cross-sectional studies, narrative reviews, systematic reviews, and meta-analyses published over the past two decades, focusing on the impact of intraoral piercings on the oral mucosa. The selected publications were descriptively analyzed according to the reported types of oral mucosal changes.

Articles unrelated to oral mucosal complications or focused exclusively on extraoral piercings were not considered relevant for the objectives of this review. As a narrative review, this study did not involve the collection of primary data. Therefore, elements such as sample size, control groups, or the use of questionnaires were not applicable. Furthermore, a formal systematic review protocol, such as PRISMA, was not followed.

The studies in this narrative review are presented in chronological order to facilitate a clear overview of the evolution of the literature

published over the past two decades (Table 1). Given the heterogeneity of the available literature, encompassing different study designs such as case reports, narrative reviews, cross-sectional studies, systematic and meta-analyses, the findings are interpreted in a descriptive manner rather than through formal weighting or quantitative comparison. Greater consideration is given to higher-level evidence, including systematic reviews, meta-analyses, and cross-sectional studies, whereas case reports and narrative reviews are considered to offer additional clinical insights and contextual understanding.

Table 1. Narrative synthesis of the included studies.

Authors	Type of Study	Research Aim	Methodology	Result
Leo-Francois et al. [4]	Narrative Review	To provide a general overview of immediate and delayed complications related to oral piercings.	Comprehensive literature review and clinical observation analysis.	The study reported increased risks of swelling, hemorrhage, gingival recession, hyperplastic and scar tissue formation, galvanic effects, and dental fractures.
Escudero-Castano, et al. [5]	Clinical Review	To classify and describe the most common oral complications in piercing users.	Analysis of clinical cases and existing medical literature.	The study found frequent occurrences of granulomatous inflammation, painful ulceration, infections, erythema, hyperplastic and hypertrophic scarring, taste alterations, mucoceles, inflammatory fibrous hyperplasia, traumatic fibroma, Miller class I and II gingival recession, and tooth chipping.
Hornecker, E., et al. [1]	Case Series and Review	To evaluate complications associated with tongue piercing.	Clinical presentation of 3 specific cases combined with a narrative review.	The study reported that tongue piercing may cause both short- and long-term complications, including pain, swelling, bleeding, infections, dental fractures, gingival recession, soft tissue trauma, and irritation fibroma formation. The presented cases also demonstrated embedding of the piercing and periodontal complications associated with tongue piercing.
Patussi C., et al. [6]	Case Report	To describe a specific pathological reaction (pyogenic granuloma) linked to piercing trauma.	Detailed clinical and histopathological analysis of a single patient case.	The study confirmed that chronic irritation caused by oral piercings can result in reactive soft tissue lesions, such as granulomas.

Samoilenko A. V., et al. [7]	Cross-sectional study	To assess complications associated with oral piercings and students' knowledge of the risks.	The study included 37 cases of oral piercings in 36 female patients (mean age 22.3 years) through clinical and radiological assessments, and surveyed 200 dental students on their awareness of piercing-related risks.	The study reported that oral piercings often cause immediate complications such as pain, swelling, and bleeding, as well as long-term issues including tooth fractures, gum recession, and mucosal atrophy.
Ledan – Muntean Szende, Tudor Bianca [8]	Case Report	To detect, differentiate, and manage a candidal lesion linked to a recently applied tongue piercing.	A clinical case report on a single patient, including a clinical evaluation and microbiological investigation of a lesion associated with a tongue piercing.	The study identified a candidal lesion clearly associated with a recent tongue piercing, accompanied by local infection, burning sensation, altered taste, and difficulty swallowing.
Saccomanno S., et al. [9]	Review & Case Report	To evaluate the oral and periodontal complications associated with lip and tongue piercings.	The study combined a literature review of 13 articles (2002-2019) on oral and periodontal piercings with two case reports of patients experiencing dento-periodontal complications.	The study confirmed a high prevalence of gingival recession, mechanical trauma, and inflammatory changes associated with oral piercings.
Passos, P., et al. [10]	Systematic Review & Meta-analysis	To quantify the risk of oral lesions and manifestations associated with oral piercings through statistical synthesis	The study conducted an extensive search of PubMed, Scopus, Embase, and Web of Science, including 54 studies with quality was assessed using JBI, and GRADE, following PRISMA guidelines.	The study reported that the most common complications of oral piercings included gum recession, tooth damage, and mucosal injuries, with other issues such as pain, infections, inflammation, and bleeding also frequently observed.
Malcangi, G., et al. [2]	Scoping Review	To analyze the local and systemic complications	The Review includes 10 articles selected from 501 studies identified in PubMed, Web of Science, Scopus. The PRISMA methodology WAS used to select the studies.	The study highlighted both local and systemic complications of oral piercings, noting that irreversible damage to the soft and hard tissues of the oral cavity may occur.
Mosaddad, S., et al. [11]	Systematic Review	To evaluate the association between oral piercings and oral complications, as well as the level of awareness among	A systematic review conducted in accordance with the PRISMA and Cochrane guidelines. Studies from	The study provided limited but suggestive evidence that oral piercings may be associated with bacterial and fungal colonization, periodontal pathogens, gingivitis, tooth fractures, enamel cracks,

		the public	PubMed, Scopus, and Google Scholar were reviewed through April 2023. Of the 965 initial articles, 34 were included in the final analysis.	plaque accumulation, inflammation, bone loss, as well as bleeding and swelling.
Masood, M., et al. [12]	Systematic Review	To investigate the biochemical impact of metal ion release on the oral mucosa.	A systematic review following PRISMA included 25 studies identified from database searches (Cochrane, Medline, PubMed, Embase, Scopus, Web of Science) conducted between October and December 2022.	Only 2 studies reported hypersensitivity and changes, while gingival recession was documented in several studies. Swelling, pain, infection, and inflammation were also observed, and tooth chipping-particularly associated with tongue piercings-was reported in multiple studies.
Dave Manas [13]	Systematic Review	To assess the complications and side effects of oral piercings on oral health.	A systematic review searched PubMed, Scopus, Cochrane, and Google Scholar up to April 2023, including 34 studies: 4 cross-sectional, 19 case series, 9 case-control, and 2 cohort studies.	The study found that lip and tongue piercings can contribute to dental fissures and depressions on teeth in direct contact with the jewelry.
Dias, D., et al. [14]	Case Report	To investigate the risks and complications of oral piercings and the dentist's role in prevention and education.	The study describes 5 clinical cases of patients with oral piercings, highlighting severe dental and periodontal complications observed in clinical practice.	Oral Piercings can cause gum recession, tooth damage, and permanent cosmetic changes, with both local and systemic effects, highlighting the need for dental monitoring.
Masood, M., et al. [15]	Cross-sectional Study	To assess knowledge and awareness of dental complications related to oral piercings among piercing users, non-users, and professionals.	A cross-sectional study in South-East Queensland, Australia, included 54 individuals with oral piercings, 54 controls without piercings, and 35 piercings professionals from dental clinics and piercing studios.	The study reported a low level of awareness among both piercing users and professionals, with common complications including chipped teeth and gum recession; additionally, most individuals frequently manipulate their oral jewelry.
Rojas-Rueda S., et al. [16]	Narrative Review	To assess the effects of tongue piercings on oral health and the associated complications.	A clinical review of articles, observational studies, and other reviews on tongue piercings and oral complications, based on searches in PubMed, Google	The study found that tongue piercings are associated with tooth fractures, gingival recession, enamel wear, tissue overgrowth, and local or systemic infections, with risks increased by poor oral hygiene, repeated trauma, and prolonged

Tkachenko IM., et al. [17]	Narrative Review	To analyze the effects of oral piercing on the oral mucosa and dentofacial system.	Scholar, Scopus, Web of Science between January 1990 to April 2025.	contact with the jewelry.
			Anarrative review of scientific articles from PubMed, Scopus, Web of Science, and Google Scholar (1990-2024)	The study found that oral piercing may cause local and systemic complications, including gingival recession, tooth damage, infections, and chronic trauma to oral tissues.

1. Definition and General Information

An intraoral piercing involves inserting jewelry through a transmucosal puncture in the oral cavity, where the ornament is placed and secured [9,16]. These have gained popularity, especially among young people, primarily for differentiation, self-expression, rebellion, or simply to be fashionable [16,18,19]. At the same time, among many people, intraoral piercings carry religious and traditional connotations, embodying the values of a cultural entity and a collective identity. There are several types of intraoral piercings which, depending on their location, take various forms specific to the areas where they are inserted. The literature highlights various intraoral sites for piercing, including the tongue, lips, lingual frenulum, labial frenulum, uvula, and cheek [9,16].

2. Mucosal changes caused by intraoral piercings

2.1. Hyperplastic changes

The oral mucosa is constantly exposed to various internal and external stimuli that can cause a wide range of changes from reactive and inflammatory to neoplastic lesions [20]. Hyperplastic changes or so-called "reactive changes" in the mucosa represent an exuberant response to chronic mechanical irritation triggered by an intraoral factor. These can also be classified as generalized or localized non-neoplastic lesions that develop in chronic and recurrent tissue lesions arising from prolonged

jewelry wear and continuous contact with oral structures [20,21]. Hyperplastic mucosal changes in the oral cavity are, in general, a common phenomenon in clinical practice [22]. These may appear in the oral cavity as pyogenic granulomas, peripheral giant cell granulomas, irritation fibromas, or peripheral ossifying fibromas, most commonly manifesting on the gums and tongue [23–25]. Although diverse, the striking similarities among hyperplastic pathologies pose a challenge for diagnosing and identifying each specific condition [22].

2.1.1. Irritation Fibroma

Irritation fibroma presents a reactive hyperplasia of connective tissue in response to an irritant factor or chronic local microtrauma [26]. It takes the form of a nodular lesion with a smooth surface, a normal appearing overlying mucosa, and a sessile or pedunculated base with exophytic growth [27]. It is asymptomatic and painless, of variable consistency, and may present with ulcerations or signs of inflammation if it interferes with occlusion or is subjected to other local trauma [26]. Although it is described in the literature as one of the most common benign tumors in the oral cavity, classifying the fibroma as a benign tumor is incorrect, as it rarely exceeds 2 centimeters in size [27]. Fibromas can occur in various intraoral sites, including the lingual, labial, and jugal mucosa and the palate, with the most common locations being the tongue and the gingival mucosa, as illustrated in Figure 1, which shows a traumatic fibroma located on the dorsal surface of the tongue at the site of insertion, accompanied by localized atrophic changes of the surrounding mucous membrane,

highlighting the mucosal response to prolonged mechanical contact in a 22-year-old patient who has worn the piercing for six years. [27,28]. Its location correlates with the site of jewelry insertion and the anatomical structure it contacts, and it often occurs on the tongue and palate [1,7]. Treatment of the irritation fibroma involves removal of the piercing and

complete excision of the lesion, including its implantation base, with the excision performed 2 mm beyond its clinical margins into healthy tissue [27]. The prognosis for irritation fibroma is excellent; the recurrence rate is very low if the excision was complete, and the mucosa is no longer subjected to trauma [29].

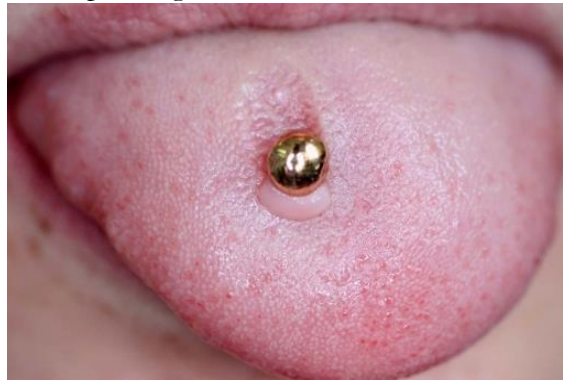

Figure 1. A traumatic fibroma located on the dorsal surface of the tongue at the site of insertion of a tongue piercing in a 22-year-old patient who has worn the piercing for six years, accompanied by localized atrophic changes of the surrounding mucous membrane, highlighting the mucosal response to prolonged mechanical contact. [7]

Reproduced from Samoilenko AV, et al. [7], licensed under CC BY 4.0

2.1.2. Pyogenic granuloma

Pyogenic granuloma is a benign, non-neoplastic lesion of the oral cavity, believed to be an excessive tissue reaction to local irritation or trauma [30]. It was first described in the scientific literature in 1844 by Hullihn, who initially misnamed it Botryomycoma, believing it to have an infectious etiology [27]. The term “pyogenic granuloma” does not reflect the true etiology of the lesion, as it is not a granuloma but a hyperplasia with a granulomatous appearance [27]. Clinically is a pedunculated or sessile pseudotumoral mass measuring a few millimeters, and its color can vary from pink to deep red or purple, depending on the age of the lesion. [6] It may also have a smooth, globular surface or present ulcerative areas that bleed at the slightest trauma. It has a rapid, asymptomatic evolution that eventually stabilizes [27]. Patients with intraoral piercings may present a pyogenic granuloma that appears as a botryomycoma. The etiological factor is traumatic irritation, and it occurs on the dorsal or ventral surface of the tongue, on the gingival mucosa in contact with the lower lip piercing, or around the lingual and labial frenula.

Treatment of pyogenic granuloma involves its excision with the incision extending 2 mm into healthy tissue to reduce the risk of recurrence. Removal of the jewelry is also an imperative requirement [27].

2.2. Inflammatory Changes

2.2.1 Traumatic mucositis

Traumatic mucositis is a localized inflammation of the oral mucosa resulting from the destruction of the epithelial layer following exposure to a local traumatic factor [29,31]. It presents as a localized lesion, accompanied by erythema, with painful symptoms when oral hygiene is poor, and it may occur on the gingival mucosa and palate [10,32]. These lesions have a favorable prognosis; they are reversible within 2 weeks following the removal of the piercing, improved oral hygiene, and the application of protective, antiseptic gels [33].

2.2.2. Chronic Ulcerations

Chronic ulcerations are also classified as a common complication caused by the mucosa's exposure to continuous mechanical trauma [11,16]. These ulcerations are

histopathologically characterized by persistent inflammation and epithelial destruction, and clinically present as well-defined oval ulcerative lesions with erythematous, slightly elevated margins, sometimes indurated, and with a base covered by a fibrinous pseudomembrane that can be removed by wiping [34]. The adjacent tissues show signs of inflammation, and the persistence of the piercing leads to chronicity of the lesion. Symptoms include pain, a burning or stinging sensation during chewing, speaking, or contact with various irritating foods, discomfort, local hypersensitivity, and slight bleeding [34,35]. As these lesions become chronic, the pain decreases intensity, but the discomfort remains until the jewelry is removed. Chronic ulcerations occur due to continuous friction between the oral tissues and the piercing, specifically on the ventral or dorsal surface of the tongue, on the gingival and buccal mucosa [36].

2.3. Atrophic Changes

Atrophic changes encompass all alterations that occur in the tissue in the context of local

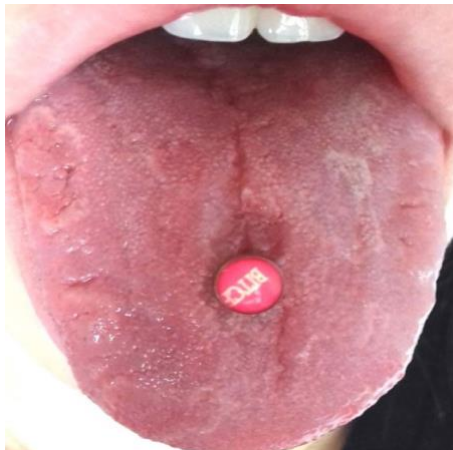


Figure 2. Localized atrophic changes of the dorsal surface of the tongue in contact with a barbell piercing in a 21-year-old patient who has worn the piercing for five years, highlighting the tissue response to prolonged mechanical trauma at the piercing site. [7] Reproduced from Samoilenko AV, et al. [7] licensed under CC BY 4.0[7]

2.4. Other Changes in the Oral Mucosa

The human body is a remarkable expression of biological balance, in which every system and process works in harmony to maintain internal equilibrium and optimal functioning [39]. This natural ingenuity is evidenced by continuous

or systemic factors. They present a multifactorial etiology, including chronic trauma, chemical, infectious, and nutritional factors, that involve thinning of the epithelium and a reduction in cellular and extracellular. Atrophy cannot be classified as a defensive process, but rather as a regressive change in the mucosa, indicating a disruption of the balance between regeneration and harmful factors [37]. Clinically, the mucosa in contact with the jewelry becomes glossy and smooth and may be slightly erythematous (Figure 1). As resistance is lost, the tissue becomes vulnerable to external factors, sometimes leading to irritation and ulceration [38]. In cases of lingual atrophy associated with tongue piercing, the affected area of the tongue shows loss of papillae, exhibits sensitivity, and sometimes taste alterations [5]. Furthermore, the literature has documented cases of *Candida albicans* colonization when the epithelial barrier is compromised, and the tissue is vulnerable [8]. Atrophy usually occurs near the jewelry insertion site, as illustrated in Figure 2, and can result in frequent gingival retraction with exposure of the tooth roots.[15].

adaptability to various stimuli, including the repeated mechanical trauma of oral piercing on the oral mucosa. Once mechanical trauma is triggered, the human body responds to this stimulus through several defense mechanisms, characterized by traumatic hyperkeratosis, reactive healing processes, and a foreign body reaction [40]. These processes represent the

body's response to the causative factor and are interpreted as protective tissue adaptations.

One of the common epithelial responses is hyperkeratosis, which is based on the thickening of the keratin layer [40]. Clinically, it appears as whitish, light-gray thickening localized at the points of contact with the jewelry, with a slightly irregular outline and a firm texture on palpation compared to the surrounding mucosa; in cases of continuous abrasion from the piercing, it may present superficial crusts. It is usually asymptomatic, but a slight sensation of discomfort may occur, with pain appearing once ulceration sets in. It has a favorable prognosis if the jewelry has been removed [10]. Another mechanism of adaptation and defense of the mucosa against chronic irritants involves the processes of scarring and fibrosis. Although they seem similar, each involves a distinct mechanism that serves the same purpose: defense and healing. Fibroblasts play a crucial role in the healing process; they initiate tissue repair, build the extracellular matrix, control remodeling, and limit excessive scarring [41,42]. These key cells produce collagen and the extracellular matrix and are fully involved in tissue remodeling [41]. Scarring itself is classified as a healing process, involving rapid repair with minimal scarring, due to the remarkable regenerative properties of the oral epithelium [42,43]. The mucosa undergoes several stages, such as hemostasis, inflammation, cell proliferation, and remodeling, to regain its integrity and functionality [44]. In the case of long-term intraoral piercing wearers, the healing process undergoes certain changes, becoming chronic scarring [39,41]. In this case, the mucosa undergoes a long-term adaptation process, and repetitive microtraumas around the jewelry lead to constant regeneration of the epithelial tissue. Clinically, chronic scarring presents as mucosal thickening at the piercing insertion site, with pale or hyperemic margins that are slightly firm to the touch [39,42]. It usually does not affect phonetic or masticatory function but may cause mild sensitivity and discomfort.

Chronic fibrosis is also a mechanism for healing and protecting the mucosa in response to irritative trauma, characterized by a constant deposition of collagen and extracellular matrix

proteins, clinically observed as a capsule of fibrous tissue located around the jewelry. The mucosa thickens, loses elasticity, may be slightly hyperemic, and presents a risk of chronic inflammation [11,16]. It is remarkable that in the case of intraoral piercings, chronic fibrosis is preceded by another interesting process called the foreign body reaction and involves an immune response from the body [11]. In other words, the intraoral presence of the jewelry triggers an immune response in which macrophages and inflammatory cells attempt to surround the foreign object to isolate it and limit tissue damage [11,12,45]. This inflammatory infiltrate initiates tissue remodeling processes, namely fibrosis, with the aim of healing and protecting the lesion [12,45].

2.5. Indirectly Associated Changes

Intraoral piercings, in addition to causing chronic mucosal irritation, indirectly affect a wide range of anatomical structures, with a broader impact than might be initially anticipated. The microtraumas, pressure, and friction caused by the piercing can directly and indirectly, reversibly and irreversibly, damage the dento-periodontal tissues [14]. Direct changes refer to inflammatory, hyperplastic, and atrophic lesions of the oral mucosa, whereas indirect changes involve effects on dental and periodontal structures. While the primary focus of this article is on mucosal changes, the indirectly associated changes cannot be overlooked. Following a review of the specialized literature, the most frequently documented changes indirectly associated with piercings are gingival recession, dental fractures, enamel abrasion, and periodontal lesions [14,17]. This perspective underscores the importance of careful monitoring and comprehensive evaluation of patients who wear such jewelry.

Gingival recession refers to the process of the gingival margin retracting apically, resulting in the gradual exposure of the root and the creation of a visually elongated tooth appearance [46]. Among the causal factors of this condition is local trauma caused by intraoral jewelry, with the degree of recession correlating with the location and duration of

wear [45,47,48]. Therefore, an increased incidence of gingival recession is observed in the upper and lower incisors among individuals with labial piercings, and in the lower anterior teeth among those with lingual piercings, as illustrated in Figure 3, which demonstrates localized gingival recession at the affected teeth adjacent to the piercing sites in a 27-year-old patient who has worn the labret piercing for three years, highlighting the impact of

prolonged mechanical trauma on gingival integrity.[47]. The progression of this process can be halted by removing the piercing and reducing inflammation, but the gingival defect may, unfortunately, remain [46]. Consequently, gingival recession is most often classified as an irreversible lesion, and reattachment of the gingiva to its initial level can be achieved through surgical methods.

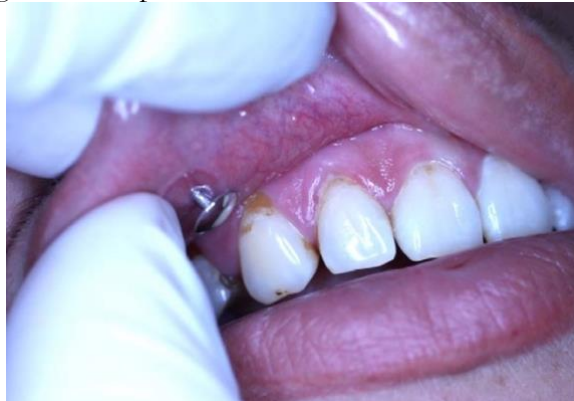

Figure 3. Localized gingival changes, including recession, in a 27-year-old patient who has worn a labret piercing for three years, with gingival recession at the upper right canine (tooth 1.3) and other affected teeth adjacent to the piercing site, emphasizing the effect of prolonged mechanical trauma on gingival integrity [7]
Reproduced from Samoilenko AV, et al. [7], licensed under CC BY 4.0

Another tissue exposed to continuous trauma and damage is the enamel, or more precisely, the entire dental crown of the teeth, which, due to continuous contact with the oral piercing, can suffer abrasions, microcracks, or even cause dental fractures. Figure 4 reproduced

from Samoilenko AV, et al. illustrates traumatic changes on the upper central and lateral incisor caused by manipulation of a tongue piercing. These changes are consistent with previous reports indicating that repetitive trauma can lead to enamel wear [7].

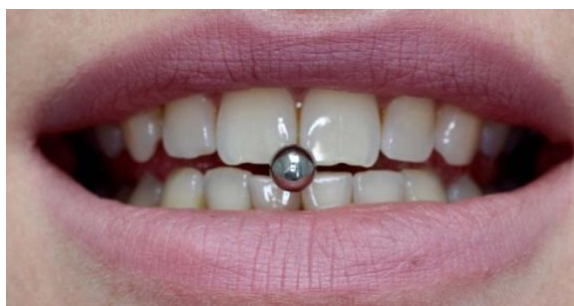

Figure 4. Traumatic changes of the upper central and lateral incisors (teeth 1.1, 1.2, and 2.1) resulting from repeated manipulation of a tongue piercing, emphasizing the mechanical impact of prolonged contact between the jewelry and the teeth. Reproduced from Samoilenko AV, et al. [7], licensed under CC BY 4.0

These are compounded by parafunctions, or parafunctional habits of biting and striking the jewelry. Unfortunately, these constitute irreversible lesions that can lead to complications involving the dentin and even the pulp chamber [13]. Another category of changes frequently induced by the presence of

intraoral piercings is periodontal lesions [13]. These manifest as damage to the marginal periodontium, the onset of gingival inflammation, and the formation of periodontal pockets, and clinical attachment loss is frequently observed in areas exposed to contact with the jewelry [13,17]. Another

aggravating factor in these lesions is the accumulation of biofilm attached to the surface of the piercing, which, through direct contact with the damaged tissue, contributes to the onset of oral microbiota dysbiosis [13]. Removal of the jewelry and treatment of periodontal lesions are imperative for restoring the health and integrity of the periodontium.

Results

Intraoral piercings have been investigated in a range of studies, including high-level evidence syntheses (systematic reviews and meta-analyses, such as those conducted by Saccomanno S., et al [9], Dave Manas [13], Masoos M., et al [15], Mosaddad S., et al [11] and Passos P., et al [10]) as well as narrative reviews, observational studies, and case reports. This methodological diversity reflects significant heterogeneity in the available literature.

Inflammatory lesions:

All analyzed studies reported inflammatory changes in the oral mucosa, including traumatic mucositis and chronic ulcerative lesions. Escudero-Castano N. et al. [5] reported the presence of ulcerations at the piercing insertion site, while traumatic ulcerations were consistently described in the studies conducted by Samoilenko AV. et al.[7], Masood M. et al.[12], Tkachenko IM. et al.[17][17], and Rojas Rueda S. et al.[16]. In addition, Saccomanno S. et al.[9] highlighted the occurrence of ulcerations at the level of the gingival margin, whereas Passos P. et al., [10] and Malcangi G. et al. [2] frequently reported soft tissue and mucosal injuries, inflammation, and other oral mucosal changes associated with oral piercing.

These lesions were frequently associated with pain, erythema, edema, and delayed healing.

Hyperplastic changes:

Ten of the included studies described hyperplastic changes, most commonly irritation fibroma and pyogenic granuloma. Hornecker E. et al.[1], Tkachenko IM, et al. [17], Leo-Francois et al. [4], identified the occurrence of irritation fibroma at the site of

lingual piercing insertion, mentioning that its development was due to continuous traumatic stimulation of the mucosa. Patussi C. et al. [6]presence of pyogenic granuloma on the dorsal surface of the tongue following the use of a lingual piercing, while granulomatous changes were also described by Leo-Francois MR. et al. [4] and Dias D. et al. [14]. These changes were observed as reactive responses to repetitive mechanical contact between the oral jewelry and adjacent soft tissues.

Atrophic changes:

Nine studies reported atrophic mucosal alterations, primarily in areas exposed to constant friction. In the study by Ledan-Muntean Szende and Tudor Bianca, candida albicans colonization was observed when the epithelial barrier was compromised, leaving the tissue more vulnerable. [8]

Other mucosal changes:

Leo-Francois MR. et al. [4], Escudero-Castano N. et al [5], and another 11 studies described additional mucosal changes, including hyperkeratosis, fibrosis, and scar formation, which were interpreted as tissue responses to chronic mechanical stress and repeated trauma.

Indirectly associated changes:

Rojas-Rueda et al. [16], Mosaddad S. et al. [11], Masood M. et al. [15], Dave Manas [13] and another 10 of the included studies reported indirectly associated oral complications, including gingival recession, dental fractures, enamel abrasions, and periodontal lesions.

Note: These results are presented objectively, as a synthesis of the literature, without interpretation or clinical recommendations, to meet the requirement for a clear Results section.

Discussion

A critical analysis of the literature indicates that, despite methodological differences, there is a clear consensus regarding the traumatic and irritating effects of intraoral piercings on oral mucosa. Inflammatory, hyperplastic, and

atrophic changes are frequently reported, suggesting that intraoral jewelry acts as a chronic mechanical stressor.

Methodological heterogeneity among studies affects the strength and reliability of the conclusions. High-level evidence supports the local mucosal complications, whereas systemic or microbiological effects are less consistently documented, relying on limited evidence. This highlights the need for cautious interpretation and avoidance of overgeneralization.

Comparative analysis shows consistency in the types of changes reported across studies, but variability exists in their frequency and severity, likely due to differences in patient populations, jewelry type, and duration of exposure. Hyperplastic changes, such as irritation fibroma and pyogenic granuloma, are consistently described, though reported prevalence varies, indicating potential context-dependent influences.

Indirect changes, including gingival recession and dental fractures, demonstrate that the impact of piercings extends beyond the directly affected mucosa.

Overall, the reviewed literature confirms that intraoral piercings act as chronic traumatic factors for the oral mucosa. At the same time, differences in study design and limitations highlight the need for further research using standardized protocols to evaluate the prevalence, severity, and mechanisms of piercing-associated changes more precisely.

Future Directions

Although intraoral piercings have been studied for several decades, a promising direction for future research would be the development of practical, evidence-based guidelines for both patients and clinicians. Such guidelines could include standardized recommendations for piercing care, hygiene practices, and early warning signs that should prompt professional evaluation. Implementing these guidelines could serve as a valuable educational tool, helping to reduce the incidence of mucosal changes among individuals with intraoral

piercings and promoting safer oral health practices.

Conclusions

The review highlights that oral piercings are not merely cosmetic accessories but can have significant adverse effects on oral mucosal health. Their impact extends beyond aesthetics, as a repetitive mechanical trauma can compromise tissue integrity and trigger a broad spectrum of mucosal changes. Under conditions of poor hygiene or additional trauma, minor lesions may progress to clinically significant changes, potentially affecting the patient's overall oral health.

Dentists play a crucial role in the early detection and management of these lesions, guiding patients with informed advice and strategic interventions. Finally, the reviewed studies demonstrate the inherent ability of the human body to respond to localized injury through self-regulating and reparative mechanisms, even under conditions of chronic mechanical trauma.

Author Contributions (CRediT Taxonomy)

Conceptualisation: M.A.M.; G.G., Data curation: E.B., Formal analysis: E.B., Investigation: M.A.M.; G.G., Methodology: E.B.; M.A.M.; A.E.P, Software: E.B.; A.E.P Writing original draft: G.G.; Writing review and editing: E.B.; A.E.P; Supervision: M.A.M. Validation: G.G.; M.A.M.; E.B.

Disclaimer/Publisher's Note

The authors alone are responsible for the content of this article. The validity, accuracy of data and views expressed are solely those of the author(s) and do not necessarily reflect those of their affiliated institutions, the publisher, the editors, or the reviewers. Any product evaluated or claim made by its manufacturer is not guaranteed or endorsed by the publisher.

Conflict of interest

None to declare.

Funding

No external funding was received.

Generative AI Statement:

During the preparation of this work the author used Grammarly to improve grammar and punctuation. After using this tool, the author reviewed and edited the content as needed and are fully responsible for the originality and integrity of the content of the article.

References

- Hornecker E, Mausberg RF, Ziebolz D, et al. Complications of Tongue Piercing: A Review of the Literature and Three Case Reports. *J Contemp Dent Pract* 2009;10:65–71. <https://doi.org/10.5005/jcdp-10-6-65>.
- Malcangi G, Patano A, Palmieri G, et al. Oral Piercing: A Pretty Risk—A Scoping Review of Local and Systemic Complications of This Current Widespread Fashion. *International Journal of Environmental Research and Public Health* 2023;20 (9):5744. <https://doi.org/10.3390/ijerph20095744>.
- Moutsopoulos NM, Konkel JE. Tissue-Specific Immunity at the Oral Mucosal Barrier. *Trends Immunol* 2018;39:276–87. <https://doi.org/10.1016/j.it.2017.08.005>.
- Maheu-Robert LF, Andrian E, Grenier D. Overview of complications secondary to tongue and lip piercings. *Journal of the Canadian Dental Association*, 2007;73(4).
- Escudero-Castaño N, Perea-García MA, Campo-Trapero J, et al. Oral and perioral piercing complications. *The Open Dentistry Journal*, 2008;2:133.
- Patussi C, et al. Oral Pyogenic Granuloma After Tongue Piercing Use: Case Report. *Dentistry* 2014;4(5):1. <https://doi.org/10.4172/2161-1122.1000229>.
- Samoilenko AV, Orishchenko VY, Strelchenia TN, et al. Oral Piercing is a new challenge in the dentistry. *Medicni Perspektivi*. 2019;24(4):133–44. <https://doi.org/10.26641/2307-0404.2019.4.189605>.
- Ledan-Muntean S, Tudor B. Colonization of Candida After the Placement of a Tongue Piercing, a Case Report. *Acta Medica Transilvanica* 2020;25:63–5. <https://doi.org/10.2478/amtsb-2020-0076>.
- Saccomanno S, Ieria I, Manenti RJ, et al. Complications of oral piercing: a review of the literature and two case reports. *J Biol Regul Homeost Agents*. 2021;35:167–78.
- Passos PF, Pintor AVB, Marañón-Vásquez GA, et al. Oral manifestations arising from oral piercings: A systematic review and meta-analyses. *Oral Surgery, Oral Medicine, Oral Pathology and Oral Radiology*, 2022;134:327–41. <https://doi.org/10.1016/j.ooolo.2022.04.051>
- Mosaddad SA, Talebi S, Hemmat M, et al. Oral Complications Associated with the Piercing of Oral and Perioral Tissues and the Corresponding Degree of Awareness among Public and Professionals: A Systematic Review. *Diagnostics* 2023;13. <https://doi.org/10.3390/diagnostics13213371>.
- M. Masood · L. J. Walsh · S. Zafar. Oral complications associated with metal ion release from oral piercings: a systematic review. *European Archives of Paediatric Dentistry* 2023;24:677–90. <https://doi.org/10.1007/s40368-023-00831-0>.
- Dave M. EBD spotlight: The impact of oral piercings on oral health. *BDJ Team* 2024;11:288–9. <https://doi.org/10.1038/s41407-024-2721-0>.
- Dias D, Flores PC, Hilgenberg SP, et al. Risks and Complications in the Use of Oral Piercing—Clinical Cases Report. *Journal of Pathology Research Reviews & Reports*. SRC/JPR-185. 2024;168:2-15. [https://doi.org/10.47363/JPR/2024\(6\)168](https://doi.org/10.47363/JPR/2024(6)168).
- Masood M, Walsh LJ, Zafar S. Awareness of dental complications with oral piercings. *Oral Dis* 2024;30:4404–11. <https://doi.org/10.1111/odi.14908>.
- Rojas-Rueda S, Citrin NS, Antal MA, et al. Impact of Tongue Piercings on Oral Health: A Narrative Literature Review. *Clin Pract* 2025;15:171. <https://doi.org/10.3390/clinpract15090171>.
- Tkachenko IM, Brailko NM, Marchenko IYa, et al. ASSESSMENT OF THE IMPACT OF ORAL PIERCING ON THE ORAL MUCOSA: REVIEW ARTICLE. 2026;26:289–93. <https://doi.org/10.31718/2077-1096.26.1.289>.
- Desai N, Breuner CC. Tattoos and Piercings in Female Adolescents and Young Adults. *J Pediatr Adolesc Gynecol* 2023;36:14–7. <https://doi.org/10.1016/j.jpog.2022.08.007>.
- Breuner CC, Levine DA, Breuner CC, et al. Adolescent and Young Adult Tattooing, Piercing, and Scarification. *Pediatrics* 2017;140. <https://doi.org/10.1542/peds.2017-1962>.
- Prasanna J, Sehrawat S. Fibroepithelial hyperplasia: rare, self-limiting condition—two case reports. *Journal of Advanced Oral Research*. 2011;3(3):63–70
- Rajendran R. Shafer's textbook of oral pathology, 6th ed. Elsevier India; 2009
- Deena P, Mugundan RN, Vinodh R, et al. Pyogenic granuloma of the tongue. *Hellenic Archives Oral Maxillofacial Surgery*. 2021;22:197–201.
- Kfir Y, Buchner A, Hansen LS. Reactive Lesions of the Gingiva: A Clinicopathological Study of 741 Cases. *J Periodontol* 1980;51:655–61. <https://doi.org/10.1902/jop.1980.51.11.655>.
- Gusterson BA, Greenspan JS. Multiple polypoid conditions of the oral mucosa. *British Journal of Oral Surgery* 1974;12:91–5. [https://doi.org/10.1016/0007-117X\(74\)90066-3](https://doi.org/10.1016/0007-117X(74)90066-3).
- Buchner A, Sandbank M. Multiple fibroepithelial hyperplasias of the oral mucosa. *Oral Surgery, Oral Medicine, Oral Pathology* 1978;46:34–9. [https://doi.org/10.1016/0030-4220\(78\)90434-6](https://doi.org/10.1016/0030-4220(78)90434-6).

26. Srivastava A, Bhati P, Khanna V, et al. A Large Irritation Fibroma of the Hard Palate: A Rare Clinical Entity. *Cureus* 2024. <https://doi.org/10.7759/cureus.62244>.
27. Bucur A, Navarro Vila C, Lowry J, et al. *Compendiu de chirurgie oro-maxilo-facială*. Bucharest: Med Publishing; 2009, vol II.
28. Tsikopoulos A, Festas C, Fountarlis A, et al. Large irritation fibroma of hard palate: A case report of a rare clinical entity. *Pan African Medical Journal* 2021;38:1–7. <https://doi.org/10.11604/pamj.2021.38.61.27662>.
29. McKinney R, Brizuela M, Olmo H. *Physical and Chemical Lesions of the Oral Mucosa Continuing Education Activity*. 2026.
30. Sachdeva SK. Extragingival Pyogenic Granuloma: an Unusual Clinical Presentation. *J Dent (Shiraz)* 2015;16:282–5.
31. Gholizadeh N, Sheykhbahaei N, Sadrzadeh-Afshar M-S. New Treatment Approaches of Oral Mucositis: A Review of Literature. *Advances in Human Biology* 2016;6:66. <https://doi.org/10.4103/2321-8568.190319>.
32. Bell A, Kasi A. Oral mucositis. In: *StatPearls* [Internet]. Treasure Island (FL): StatPearls Publishing; 2023 May 29 [cited 2026 Jan]
33. Elad S, Yarom N, Zadik Y, et al. The broadening scope of oral mucositis and oral ulcerative mucosal toxicities of anticancer therapies. *CA Cancer J Clin* 2022;72:57–77. <https://doi.org/10.3322/caac.21704>.
34. Rosa DE, Hapid MH, Hidayat W. Non-Healing Chronic Traumatic Ulcer, an Entity That Can Resemble Other Chronic Ulcers. *Int Med Case Rep J* 2023;16:585–90. <https://doi.org/10.2147/IMCRJ.S421748>.
35. Vashishat B, Sinha S, Srivastava T, et al. Management of oral aphthous ulcer: A review. *Bioinformation* 2024;20:434–8. <https://doi.org/10.6026/973206300200434>.
36. Fatima Shahid, Fatima Javed, Hashmat Gul, et al. Classification of Oral Ulcers and its Treatment by focusing on Exosome Loaded Hydrogel: A Comprehensive Review. *Journal of Health and Rehabilitation Research* 2024;4:820–30. <https://doi.org/10.61919/jhrr.v4i2.867>.
37. ALRASHDAN MS, ANDREADIS D, ZISIS V, et al. Immune-mediated oral mucosal pathology: a comprehensive review and update for clinicians - part II. *Italian Journal of Dermatology and Venereology* 2024;159. <https://doi.org/10.23736/S2784-8671.23.07690-9>.
38. Glick M, Greenberg MS, Lockhart PB, et al. *Introduction to Oral Medicine and Oral Diagnosis. Burket's Oral Medicine*, Wiley; 2021, p. 1–18. <https://doi.org/10.1002/9781119597797.ch1>.
39. Chen Y, Gao B, Cai W, et al. Oral mucosa: anti-inflammatory function, mechanisms, and applications. *J Mater Chem B* 2025;13:4059–72. <https://doi.org/10.1039/D4TB02845G>.
40. Xuanyuan X, Zhang L, Zheng Y, et al. SPRR1B+ keratinocytes prime oral mucosa for rapid wound healing via STAT3 activation. *Commun Biol* 2024;7:1155. <https://doi.org/10.1038/s42003-024-06864-5>.
41. Griffin MF, Fahy EJ, King M, et al. Understanding Scarring in the Oral Mucosa. *Adv Wound Care (New Rochelle)* 2022;11:537–47. <https://doi.org/10.1089/wound.2021.0038>.
42. Chuhuaicura P, Rodríguez-Niklitschek C, Oporto GH, et al. Distinct Molecular Mechanisms in Oral Mucosal Wound Healing: Translational Insights and Future Directions. *Int J Mol Sci* 2025;26:10660. <https://doi.org/10.3390/ijms262110660>.
43. Fournier BPJ, Nguyen NE, Durand R, et al. Oral mucosal wound healing: A photograph-based prospective study. *J Periodontol* 2026. <https://doi.org/10.1002/jper.70063>.
44. Liu X, Huang X, Liu N, et al. Advances in smart stimuli-responsive materials for oral wound healing. *Front Chem* 2025;13. <https://doi.org/10.3389/fchem.2025.1725373>.
45. Meseberg T, Kurz S, Spohn J. Foreign body reaction: towards a macrophage-centered adverse outcome pathway for fibrotic encapsulation. *Frontiers in Toxicology* 2026;8:1735871. <https://doi.org/10.3389/ftox.2026.1735871>.
46. Aden, Tjarko. *Gingival Recession and its Treatment Modalities*. Diss. Vilniaus universitetas., 2024.
47. Offen E, Allison JR. Do oral piercings cause problems in the mouth? *Evid Based Dent* 2022;23:126–7. <https://doi.org/10.1038/s41432-022-0816-z>.
48. Kanarakis I, Sandu D, Solomon SM, et al. Contemporary aspects regarding the etiology of gingival recessions: a review. *Rom J Oral Rehabil*. 2021;13:78-86

Corresponding author:

Eugen BUD

George Emil Palade University of Medicine, Pharmacy, Science and Technology of Târgu Mureș, 38 Gheorghe Marinescu street, Târgu Mureș, 540139, Romania

Email: eugen.bud@umfst.ro